

## Delayed repair of pelvic fracture urethral injuries: Preoperative decision-making

Nadir I. Osman, Altaf Mangera, Richard D. Inman & Christopher R. Chapple

To cite this article: Nadir I. Osman, Altaf Mangera, Richard D. Inman & Christopher R. Chapple (2015) Delayed repair of pelvic fracture urethral injuries: Preoperative decision-making, Arab Journal of Urology, 13:3, 217-220, DOI: [10.1016/j.aju.2015.06.008](https://doi.org/10.1016/j.aju.2015.06.008)

To link to this article: <https://doi.org/10.1016/j.aju.2015.06.008>



© 2015 Arab Association of Urology



Published online: 05 Apr 2019.



Submit your article to this journal [↗](#)



Article views: 334



View related articles [↗](#)




View Crossmark data [↗](#)



**Arab Journal of Urology**  
(Official Journal of the Arab Association of Urology)

[www.sciencedirect.com](http://www.sciencedirect.com)



**ONCOLOGY/RECONSTRUCTION  
REVIEW**

**Delayed repair of pelvic fracture urethral injuries:  
Preoperative decision-making**



**Nadir I. Osman \***, Altaf Mangera, Richard D. Inman, Christopher R. Chapple

*Department of Urology, Royal Hallamshire Hospital, Sheffield, South Yorkshire, UK*

Received 28 February 2015, Received in revised form 27 June 2015, Accepted 27 June 2015  
Available online 5 August 2015

**KEYWORDS**

Pelvic fracture urethral injury;  
Urethral distraction defect;  
Preoperative decision making

**ABBREVIATIONS**

PFUDD, pelvic fracture urethral distraction defects

**Abstract** Pelvic fracture urethral injuries comprise one of the most challenging reconstructive procedures in urology. The obliterated or stenosed urethra can usually be effectively repaired by an end-to-end anastomosis (bulbomembranous anastomosis). To achieve this, a progression of surgical steps can be used to make a tension-free anastomosis. Before undertaking surgery it is important to comprehensively assess the patient to define their anatomical defects, in particular the site of the stenosis, the length of the distraction injury and the integrity of the bladder neck, and thus guide preoperative decision-making. Contemporary reports suggest that most pelvic fracture urethral distraction defects (PFUDD) can be adequately managed by a perineal approach. Nevertheless it is essential that all surgeons treating these injuries are familiar with the whole spectrum of operative steps that are necessary to repair PFUDD.

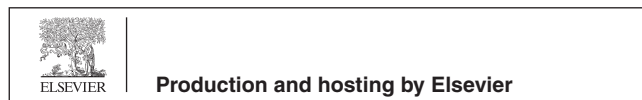
© 2015 Arab Association of Urology. Production and hosting by Elsevier B.V. This is an open access article under the CC BY-NC-ND license (<http://creativecommons.org/licenses/by-nc-nd/4.0/>).

**Introduction**

Pelvic fracture urethral distraction defects (PFUDD) are rare but potentially debilitating injuries that affect the posterior urethra. PFUDD occur in 2–25% of patients who sustain pelvic fractures [1–3], and are associated with a high risk of long-term genitourinary morbidity, which might continue long after the associated orthopaedic injuries have resolved [4]. Urological complications include urethral stenosis or obliteration, incontinence and fistula formation consequent upon a rectal injury, and erectile dysfunction which affects up

\* Corresponding author at: Department of Urology, Royal Hallamshire Hospital, Glossop Road, Sheffield, South Yorkshire S10 2JF, UK. Tel.: +44 (0)114 271 3048; fax: +44 (0)114 279 7841.

E-mail address: [nadirosman@hotmail.com](mailto:nadirosman@hotmail.com) (N.I. Osman).  
Peer review under responsibility of Arab Association of Urology.



to 35% [5] of men, significantly affect quality of life. Clearly, in these patients surgical intervention is inevitable to restore urethral continuity, and if necessary to reconstruct the bladder neck and deal with any associated rectal injury. A structured approach to the assessment of patients is essential.

Some controversy has resulted about acute intervention to effect a realignment vs. suprapubic drainage and delayed reconstruction [6]. Delayed repair is surgery deferred until coexisting orthopaedic injuries have healed at, or later, than 3 months after injury, and is the most commonly recommended approach [7]. Although success has been reported with early endoscopic intervention to shorten the distraction defect [8], early open surgery has been linked to a poor outcome, both in terms of urethral patency and for other aspects such as continence and potency rates [9,10]. These repairs are often technically challenging and require a careful and comprehensive preoperative assessment. This review considers the preoperative evaluation of patients undergoing delayed repair (usually at 3 months and later, following injury) with reference to recent published reports and contemporary consensus recommendations.

## Methods

The PubMed database was searched for articles in English published from 1960 to 2014. Search terms included 'pelvic fracture urethral injury', 'pelvic fracture urethral distraction defect', 'posterior urethral stricture', and 'bladder neck injury'. Abstracts were checked for relevance before full articles were retrieved.

## Discussion

### *Surgical approaches*

The rationale for delayed repair is to allow stabilisation of life-threatening injuries, the absorption and resolution of pelvic haematoma, and return of the bladder and prostate to a more anatomical position [11]. Most posterior urethral stenoses caused by PFUDD are short (< 2 cm) and are amenable to an anastomotic repair through a simple perineal approach, which entails adequate mobilisation of the bulbar urethra with division of the raphe between the corpora cavernosa to foreshorten the urethral course. With longer defects, a series of progressive steps ('perineal progression', 'elaborated perineal approach') can be used to mobilise the anterior urethra sufficiently to bridge defects of up to 8 cm long [12]. The surgical steps are: bulbar urethral mobilisation; separation of the crura; inferior pubectomy; and supracrural re-routing.

A combined abdomino-perineal approach [13] might be needed in cases where, e.g., there is fistulation to the rectum, or abdominal wall, when the bladder base/neck have been damaged or when the lithotomy position is not possible due to associated orthopaedic deformity.

### *Preoperative evaluation*

A thorough preoperative evaluation is essential to assess the available surgical options for repairing the defect and to diagnose any associated problems (e.g., injured bladder neck or fistula) that might require reconstruction at the time of any urethral repair. An appropriate preoperative evaluation should include the following.

- An initial clinical and anatomical assessment of the severity of the nature of the PFUDD, including a rectal examination and careful inspection of the penile and perineal skin for evidence of scarring and urethrocutaneous fistula by reference to the original retrograde urethrogram.
- A review of the bony pelvic anatomy and to consider the feasibility of operative positioning.
- Pre-operative urine culture to treat any infection and ensure antibiotic prophylaxis as appropriate.
- A synchronous retrograde urethrogram and micturating cysto-urethrogram, to determine the length of the defect and to evaluate the competence of the bladder neck.
- An antegrade suprapubic cystoscopy, both to determine the anatomical integrity of the bladder neck and to exclude any evident injuries, such as with bony spicules, and to assess the anterior urethra.

### *Assessing bladder neck function*

In PFUDD the distal urethral sphincter mechanism might be destroyed as a result of the distraction injury, and so urinary continence depends on a competent bladder neck mechanism. If the bladder neck is also damaged (direct injury or neural injury), there is a higher risk of subsequent incontinence when the urethral defect is repaired [14]. Ideally, any direct bladder neck injury should be repaired immediately to prevent urine leak, fibrosis and incontinence, but it is often the case that these injuries are not recognised at the time of initial retrograde urethrography, and often due to the severity of associated injuries this is not feasible.

To assess the functionality of the bladder neck, the International Consultation recommends an initial assessment with a micturating cysto-urethrogram followed by antegrade cystoscopy [14,15]. The bladder is filled to 100 mL and the initial film is taken, and thereafter the bladder is filled gradually. The bladder neck is observed carefully for whether it has an open appearance, indicating incompetence. It is important not to overfill the bladder, as this will both cause a supra-physiological rise in pressure which can cause the bladder neck to misleadingly appear open [14]. Likewise it must be considered that if there is an involuntary detrusor contraction, this can produce misleading appearances, by causing the bladder neck to open.

If the bladder neck is closed then this usually suggests that the bladder neck mechanism is functional. If the bladder neck is open then antegrade cystoscopy should

be done [15], which will help to clarify the situation. A radiologically open bladder neck might still be functional if the cystogram shows a funnel shape and a short length (<1 cm), and the cystoscopy shows a closed, undistorted, unscarred bladder neck. These patients should be managed conservatively, as radiological incompetence often resolves with no incontinence when the catheter is removed. Similarly, those patients where bladder neck incompetence is likely to be neurogenic (evidence of sacral root injury) should be managed conservatively. It is important to consider that except in the most severe closed injuries, or if there has been a penetrating injury, bladder neck incompetence is uncommon, occurring in <10% of cases.

Conversely, if the cystogram shows a rectangular, long (>1 cm) bladder neck and the cystoscopy shows gaping, distortion and scarring, then bladder neck dysfunction is likely and a bladder neck repair might be indicated [16,17], which will require a combined abdomino-perineal surgical approach.

The optimal timing of a bladder neck repair remains unclear, but largely depends on when the injury is recognised. The choice is between a concomitant repair of both the bladder neck and the urethral injury or performing a delayed repair of the urethra after immediate bladder neck repair [18].

At the time of assessing the bladder neck a flexible cystoscope can be passed antegradely into the prostatic urethra to assess the exact position of the PFUDD. In many cases the injury is found to be distal to the verumontanum, suggesting that after a repair there will be good residual function in the distal urethral sphincter mechanism.

#### *Assessing the anterior urethra*

Retrograde urethroscopy is important to assess the general state of the anterior urethra and exclude the presence of anterior strictures. A healthy looking anterior urethra generally indicates good tissue elasticity, which is critical to carrying out the subsequent anastomotic repair and bridging the distraction defect. Synchronous anterior strictures can compromise the blood supply to the bulbar urethra after dividing the bulbar arteries.

#### *Assessing the options as to whether anastomotic repair is unfeasible*

In the unusual event that an anastomotic repair cannot be made, a one-stage or two-stage repair can be considered [19,20]. This is almost always in the setting of salvage procedures and should only be considered after referral to a specialist unit, and with PFUDD in experienced hands is extremely uncommon.

#### *Predicting the type of approach required*

Longer defects usually require a progressive perineal approach; after an initial perineal approach, a subsequent transabdominal dissection might be indicated. As noted above, a careful preoperative assessment is important to try to predict the extent of surgery required on the basis of the radiologically assessed defect. In more complex cases, irrespective of how good the urethrography is, this might be necessary. In cases where surgery to the bladder neck is necessary, it is always indicated. Andrich et al. [21] studied 100 patients with PFUDD undergoing delayed repair after a pelvic fracture urethral injury, excluding patients undergoing salvage surgery. They found that in 38% a radiological defect (using synchronous retrograde urethrography + micturating cysto-urethrography) could not be adequately shown due to the lack of adequate visualisation of the posterior urethra. In the other 62% there was no relationship between the length of the radiological defect and the extent of surgery required. The authors concluded that any surgeon repairing PFUDD should be adequately experienced in performing all four steps in the perineal progression to achieve a tension-free anastomosis, before considering the need to progress to a synchronous abdominal approach. Conversely, in his series of 149 cases, Koraitim [22] showed that a simple perineal approach was sufficient when the defect was  $\leq 3$  cm, with defects of >3 cm requiring a progressive perineal or abdomino-perineal procedure.

More recently, Koraitim [23] proposed that the type of repair needed not only depended on the urethral defect, but also on the length of the bulbar urethra which is available to bridge it. On this basis he introduced the gapometry/urethrometry index, which is calculated by dividing the length of the urethral defect by the length of the bulbar urethra (from the blind proximal end to the bulbopenile junction). On reviewing the records of 120 patients, he found that an index of <0.35 predicted a simple perineal approach operation, whilst an index of >0.35 predicted a progressive perineal or abdomino-perineal approach [24]. The major disadvantages of this approach are that the length of the bulbar urethra depends on patient position or projection of the X-ray, and that the location of the bulbopenile junction cannot be reliably ascertained [15]. If a voiding contraction cannot be generated to open the bladder neck and fill the posterior urethra, then the defect will not be visualised [21]. Even when the posterior urethra is shown on the urethrogram there is a chance that the defect is underestimated if a urinoma is present, adjacent or continuous with the prostatic urethra [22]. Newer methods of assessment, such as multidimensional CT and MRI might offer better anatomical characterisation of the defect, surrounding scar

tissue/cavities and prostatic displacement, but are yet to be adequately evaluated in prospective studies [25,26]. Despite this, in our experience the vast majority of PFUDD consequent upon blunt trauma are amenable to a perineal approach.

## Summary

PFDD are rare and potentially complex injuries. The evidence base for the factors that are important in the preoperative planning of surgical reconstruction is extremely limited. Ultimately the surgical approach cannot always be predicted, thus experience with all the different approaches and manoeuvres that are available is of paramount importance for any surgeons carrying out this surgery.

## Key points

- Staging PFUDD based on the initial retrograde urethro-gram is difficult as the images obtained are often suboptimal.
- There is no widely accepted and validated staging system to guide the surgical treatment of PFUDD.
- Most defects resulting from PFUDD are short and can be managed with a delayed repair using a simple perineal approach.
- The radiological length of a defect, measured using synchronous retrograde urethrography and a cystogram, does not reliably predict the nature of the surgery which will be necessary.
- The bladder neck should be assessed by both cystography and antegrade cystoscopy, as a radiologically open bladder neck might still be functional.
- Any surgeon treating patients with PFUDD should be skilled in the full range of surgical techniques that might be required to repair the urethral defect.

## Conflict of interest

Professor Chapple is a Consultant and Researcher to Astellas, Pfizer, Recordati, Allergan, Lilly.

## Source of funding

None.

## References

- [1] Lowe MA, Mason JT, Luna GK, Maier RV, Copass MK, Berger RE. Risk factors for urethral injuries in men with traumatic pelvic fractures. *J Urol* 1988;**140**:506–7.
- [2] Koraitim MM. Pelvic fracture urethral injuries: the unresolved controversy. *J Urol* 1999;**161**:1433–41.
- [3] Palmer JK, Benson GS, Corriere Jr JN. Diagnosis and initial management of urological injuries associated with 200 consecutive pelvic fractures. *J Urol* 1983;**130**:712–4.
- [4] Turner-Warwick R. Prevention of complications resulting from pelvic fracture urethral injuries – and from their surgical management. *Urol Clin North Am* 1989;**16**:335–58.
- [5] Blaschko SD, Sanford MT, Schlomer BJ, Alwaal A, Yang G, Villalta JD, et al. The incidence of erectile dysfunction after pelvic fracture urethral injury: a systematic review and meta-analysis. *Arab J Urol* 2014 (epub 16.10.14).
- [6] Koraitim MM. Pelvic fracture urethral injuries revisited: a systematic review. *Alexandria J Med* 2011;**47**:181–4.
- [7] Martinez-Pineiro L, Djakovic N, Plas E, Mor Y, Santucci RA, Serafetinidis E, et al. EAU guidelines on urethral trauma. *Eur Urol* 2010;**57**:791–803.
- [8] Elliott DS, Barrett DM. Long-term followup and evaluation of primary realignment of posterior urethral disruptions. *J Urol* 1997;**157**:814–6.
- [9] Webster GD, Mathes GL, Selli C. Prostatomembranous urethral injuries. A review of the literature and a rational approach to their management. *J Urol* 1983;**130**:898–902.
- [10] Koraitim MM. Pelvic fracture urethral injuries. Evaluation of various methods of management. *J Urol* 1996;**156**:1288–91.
- [11] Chapple C, Barbagli G, Jordan G, Mundy AR, Rodrigues-Netto V, Pansodoro V, et al. Consensus statement on urethral trauma. *BJU Int* 2004;**93**:1195–202.
- [12] Webster GD, Ramon J. Repair of pelvic fracture posterior urethral defects using an elaborated perineal approach: experience with 74 cases. *J Urol* 1991;**145**:744–8.
- [13] Turner-Warwick RT. A technique for posterior urethroplasty. *J Urol* 1960;**83**:416–9.
- [14] MacDiarmid S, Rosario D, Chapple CR. The importance of accurate assessment and conservative management of the open bladder neck in patients with post-pelvic fracture membranous urethral distraction defects. *Br J Urol* 1995;**75**:65–7.
- [15] Gomez RG, Mundy T, Dubey D, El-Kassaby AW, Firdaoussaleh Kodama R, et al. SIU/ICUD consultation on urethral strictures: pelvic fracture urethral injuries. *Urology* 2014;**83**(3):S48–58.
- [16] Koraitim MM. Assessment and management of an open bladder neck at posterior urethroplasty. *Urology* 2010;**76**:476–9.
- [17] Iselin CE, Webster GD. The significance of the open bladder neck associated with pelvic fracture urethral distraction defects. *J Urol* 1999;**162**:347–51.
- [18] Mundy AR, Andrich DE. Pelvic fracture-related injuries of the bladder neck and prostate: their nature, cause and management. *BJU Int* 2010;**105**:1302–8.
- [19] Cooperberg MR, McAninch JW, Alsikafi NF, Elliott SP. Urethral reconstruction for traumatic posterior urethral disruption. Outcomes of a 25-year experience. *J Urol* 2007;**178**:2006–10.
- [20] Wadhwa SN, Chahal R, Hemal AK, Gupta NP, Dogra PN, Seth A. Management of obliterative posttraumatic posterior urethral strictures after failed initial urethroplasty. *J Urol* 1998;**159**:1898–902.
- [21] Andrich DE, O'Malley KJ, Summerton DJ, Greenwell TJ, Mundy AR. The type of urethroplasty for a pelvic fracture urethral distraction defect cannot be predicted preoperatively. *J Urol* 2003;**170**:464–7.
- [22] Koraitim MM. Post-traumatic posterior urethral strictures: pre-operative decision making. *Urology* 2004;**64**:228–31.
- [23] Koraitim MM. Predictors of surgical approach to repair pelvic fracture urethral distraction defects. *J Urol* 2009;**182**:1435–9.
- [24] Koraitim MM. Gapometry and anterior urethrometry in the repair of posterior urethral defects. *J Urol* 2008;**179**:1879–81.
- [25] Zhang XM, Hu WL, He HX, Lv J, Nie HB, et al. Diagnosis of male posterior urethral stricture: comparison of 64-MDCT urethrography vs. standard urethrography. *Abdom Imaging* 2011;**36**:771–5.
- [26] Koraitim MM, Reda IS. Role of magnetic resonance imaging in assessment of posterior urethral distraction defects. *Urology* 2007;**70**:403–6.