



Prosthetic Rehabilitation of a Hemimandibulectomy Case by Non-Surgical Approach- A Case Report

Mirella Vaz ^{a*#}, Mridula Joshi ^{a^o}, Mahesh Ghadage ^{a#} and Gunjan Daphale ^{b#}

^a *Department of Prosthodontics and Crown & Bridge, Bharati Vidyapeeth (Deemed to be University) Dental College & Hospital, Navi Mumbai, India.*

^b *Department of Prosthodontics and Crown & Bridge, Saraswati Dhanwantari Dental College and Hospital, Parbhani, India.*

Authors' contributions

This work was carried out in collaboration among all authors. All authors read and approved the final manuscript.

Article Information

DOI: 10.9734/JPRI/2021/v33i60B34636

Open Peer Review History:

This journal follows the Advanced Open Peer Review policy. Identity of the Reviewers, Editor(s) and additional Reviewers, peer review comments, different versions of the manuscript, comments of the editors, etc are available here: <https://www.sdiarticle5.com/review-history/78335>

Case Study

Received 12 October 2021
Accepted 20 December 2021
Published 22 December 2021

ABSTRACT

Hemimandibulectomy can have several consequences such as disoriented masticatory cycle, eccentric occlusion, distorted speech and facial disfigurement depending on the severity of the defect. It is challenging for the prosthodontist to rehabilitate the patients in whom osseous reconstruction has not been carried out. This clinical report describes the Prosthetic management of a patient who had undergone hemimandibulectomy due to moderately differentiated squamous cell carcinoma involving left buccal mucosa, gingivobuccal sulcus and retromolar trigone. A non-surgical approach was carried out to rehabilitate this patient, which included the fabrication of a maxillary guide flange prosthesis for correction of the frontal plane rotation and a twin occlusion prosthesis for ease of mastication. The appearance of the patient was improved drastically by the fabrication of an extraoral prosthesis.

Keywords: Hemimandibulectomy; frontal plane rotation; guide flange prosthesis; twin occlusion prosthesis.

[#]Assistant Professor;

^oProfessor;

*Corresponding author: E-mail: mirella_185@yahoo.com;

1. INTRODUCTION

Malignant tumours of the oral cavity are more destructive than other tumours [1]. Tumours of oral cavity often requires resection of some parts or whole of maxilla or mandible. In patients who have undergone hemimandibulectomy, loss of mandibular continuity leads to deviation of the mandible due to secondary scar contracture and muscle imbalances [2]. The altered muscle function results in asymmetry of face that leads to unaesthetic appearance, compromise in function and psychological setback [1,3].

There is a well-known quote by a German surgeon named *Dieffenbach* about the patient with facial disfigurement. He says *“At the sight of whom all men turn in disgust and abhorrence and at whose presence children cry and dogs bark”* [4]. This statement holds true even in the modern times. A person with disfigurement is often looked down upon. This has a deep psychological impact on such patients. Thus special consideration should be given to these patients [4,5,6].

Various treatment modalities have been tried in past for rehabilitation of hemimandibulectomy cases. Advancements in the field of maxillofacial prosthetics such as bone grafts followed by implant placement provide good anchorage for dental prosthesis. Another major advancement in mandibular reconstruction is the improvement in the microvascular surgical techniques. This includes tissues which can be autogenously grafted like free flaps, bone, connective tissue, muscle and skin. However; such treatment modalities are invasive as well as expensive. All patients may not agree to surgical treatment options. The goal of the maxillofacial prosthodontist should be to provide a prosthesis which is satisfactory in form, function and aesthetics with the available resources.

When the mandibular resection involves the body of mandible, ramus and condyle, it has been suggested that a guidance prosthesis should be constructed. Its effectiveness in correcting mandibular deviation depends on the time elapsed after surgery [4,7].

2. CASE REPORT

A 51-year-old male patient reported to the Department of Prosthodontics and Crown & Bridge with a chief complaint of difficulty in chewing food and disfigured facial appearance

as the outcome of removal of left side of lower jaw.

Patient had a habit of tobacco chewing for 15 long years before being diagnosed with oral squamous cell carcinoma. It was a moderately differentiated tumour (T4,N1,M0) involving left buccal mucosa, gingivobuccal sulcus and retromolar trigone. Patient underwent hemimandibulectomy of the left side involving the body of mandible, ramus and condyle along with left modified neck dissection 08 years back for the treatment of his condition. Reconstruction was done with Pectoralis Major Myocutaneous flap. However, no osseous reconstruction was carried out. Following the surgery, the patient had undergone radiotherapy and chemotherapy. He was instructed to perform jaw stretching exercises by using OraBite Jaw stretcher system after recovering from the surgery.

Extraoral examination showed hollowness and punched out face due to hemimandibulectomy of left side giving a very unpleasing appearance. There was facial asymmetry and deviation of mandible towards the affected side. [Fig. 1].

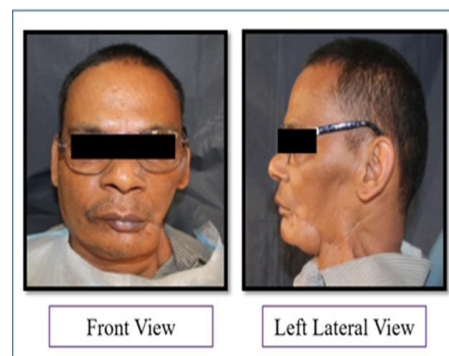

Fig. 1. Extra oral pre-operative photographs

The intra oral examination revealed inelastic scar on left buccal mucosa due to the soft tissue reconstruction of the resected region. There was loss of occlusal contact on the right side and collapsed interocclusal relation due to deviation of the mandible to the left side [Fig. 2]. The deviation was 12mm from midline. The mouth opening of the patient was reduced to 15mm. No abnormality was detected in tongue form and function.

During the hemimandibulectomy, maxillary left premolars and molars were extracted along with marginal alveolectomy of the left maxilla. On palpation, the mandibular ridge was present only up to the central incisor region on the left side.

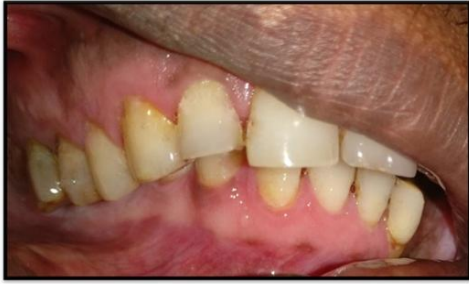

Fig. 2. Collapsed interocclusal relation

A pre-operative orthopantomograph (OPG) of the patient was done to confirm the clinical findings [Fig. 3] which revealed hemimandibulectomy of left side along with ramus and condyle and left marginal alveolectomy of maxilla with missing premolars and molars.

Cantor and Curtis, in the year 1971 classified jaw defects based on the nature of resection. According to this classification our case was Class III [8,9]. Based on history, clinical examination, radiographs and classification system our case was diagnosed as hemimandibulectomy of left side without reconstruction.

All the treatment options, surgical as well as conservative were deliberated and thought of and presented to the patient. However, the patient was reluctant to opt for the surgical approach. After obtaining patient's consent we

decided to treat the case with conservative, non surgical approach, which included guide flange prosthesis, twin occlusion prosthesis and extra oral prosthesis.

The diagnostic impressions were made for the maxillary and mandibular arches in Irreversible hydrocolloid impression material (*Zhermack-Hydrogum 5 Alginate; Italy*) using sectional impression trays [Fig. 4(a) (b)].

After disinfecting the impressions, they were poured in Type III gypsum (*Dental stone-Kalstone; Kalabhai Karson, India*) to obtain maxillary and mandibular casts [Fig. 5 (a) (b)].

For correction of frontal plane rotation, the guide flange prosthesis [Fig. 6] was fabricated for the maxillary arch. A continuous clasp was made from maxillary right canine to third molar and circumferential clasp was made on maxillary left canine. Followed by which autopolymerising acrylic resin (*DPI RR Cold Cure; India*) was used to fabricate the maxillary guide flange prosthesis.

Twin occlusion prosthesis [Fig. 7] was fabricated for the ease of mastication. In this prosthesis, a second row of teeth was arranged parallel to the patient's maxillary teeth on the palatal aspect. This row of teeth occluded with the mandibular teeth when the mandible closed in deviation. The twin occlusion prosthesis was processed using heat cure acrylic resin (*DPI Heat Cure; India*).

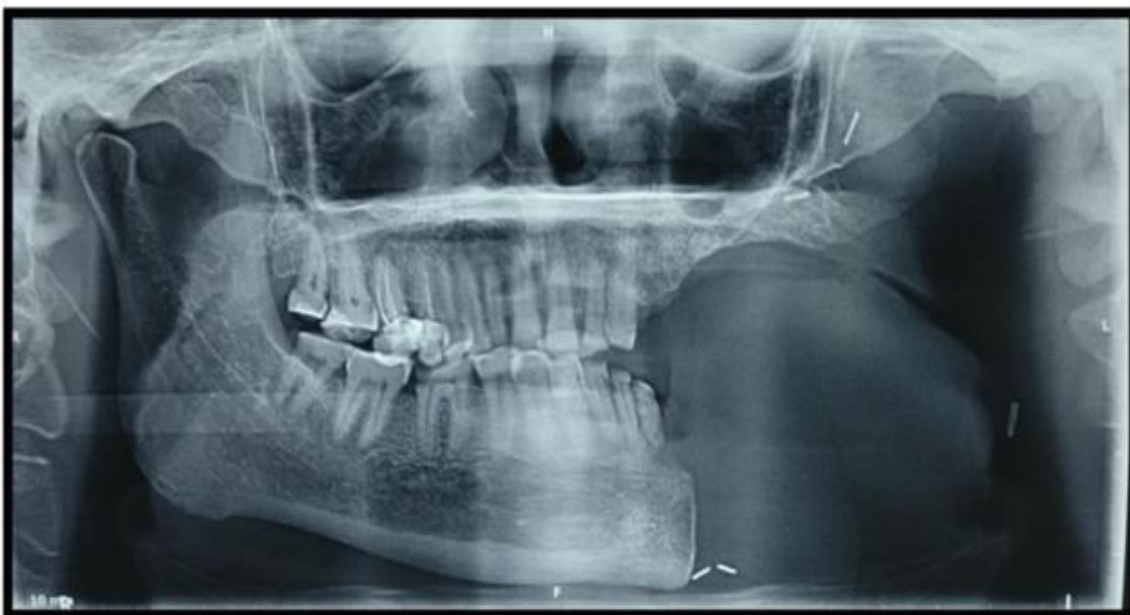

Fig. 3. Orthopantomograph (OPG)

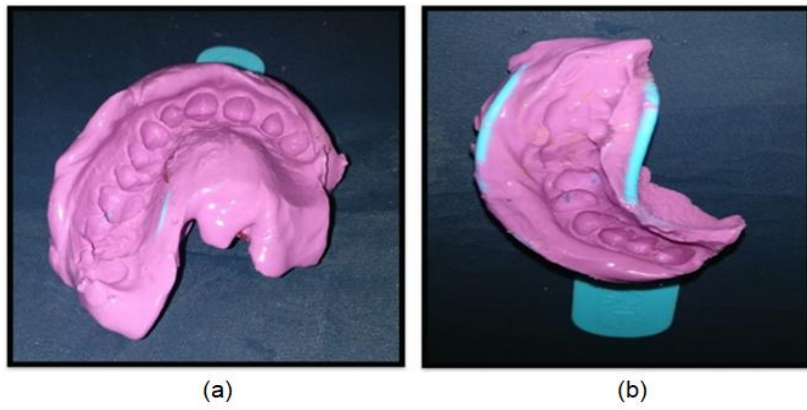


Fig. 4. Diagnostic impressions (a) maxillary arch (b) mandibular arch

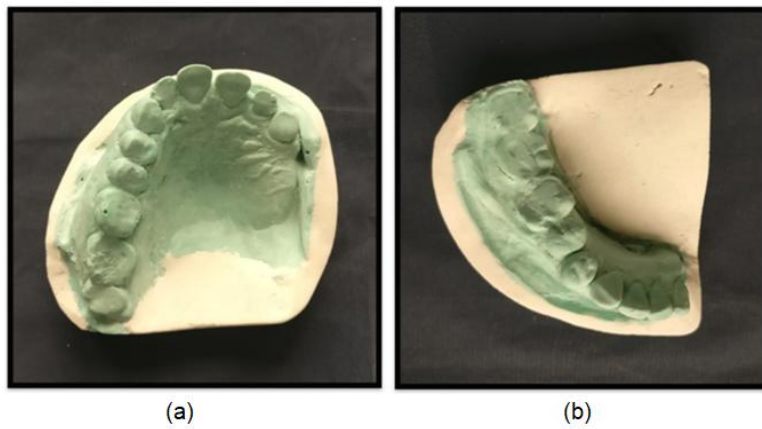


Fig. 5. (a) Maxillary cast (b) Mandibular cast

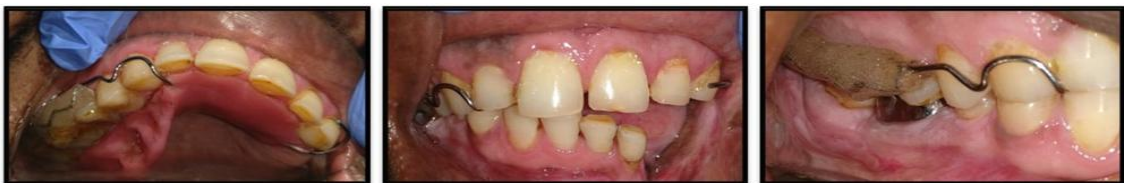

Fig. 6. Guide flange prosthesis

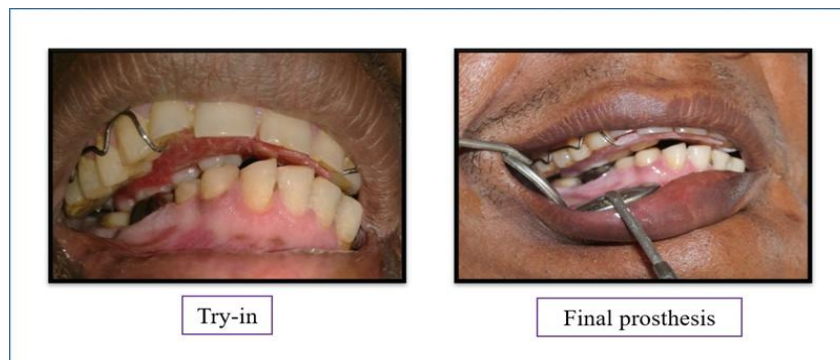

Fig. 7. Twin occlusion prosthesis

In order to enhance the facial appearance of the patient, an extra oral prosthesis was fabricated. The entire procedure was explained to the patient and he was prepared for making the facial moulage. The patient's face was boxed using boxing wax (MAARC, India), two straws were placed in his mouth for ease of breathing, petroleum gel (Vaseline) was applied on his facial hair and cotton was placed in his ears and nose to ensure that the impression material does not get entrapped in it [Fig. 8].

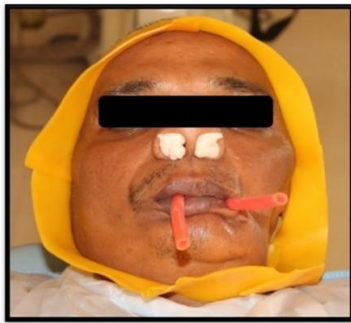

Fig. 8. Making of facial moulage

Irreversible hydrocolloid impression material (*DPI Chromatex Plus, India*) was used to make the facial moulage. Prior to the setting of the material, a wet gauze piece was placed on the impression material and secured using stapler pins. Followed by which, type III gypsum was poured onto the impression for aid in removal of the facial moulage [Fig. 9] and to prevent the tearing of the impression material during removal.

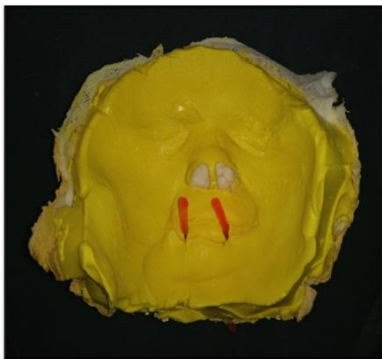

Fig. 9. Facial moulage

The facial moulage was then poured in type III gypsum (*Dental stone- Kalstone; Kalabhai Karson, India*) after disinfecting it and thus the model was obtained from the facial moulage [Fig. 10].

The wax pattern [Fig. 11] was fabricated using modelling wax (*MAARC, India*) on the model and was then tried on the patient's face to check the extent and bulk. It was extended superiorly till the spectacles of the patient, inferiorly and medially covering the entire defect and posteriorly it was extended behind the ear to engage in the anatomical undercut. The necessary corrections were done in the wax pattern during the try-in and approved by the patient.

Facial characterization was an important aspect of the treatment plan and it was meticulously done; the wax pattern was invested in type III gypsum (*Dental stone- Kalstone; Kalabhai Karson, India*) [Fig. 12]. Dewaxing was done and the moulds were obtained [Fig. 13].

Colour matching for silicone extra oral facial prosthesis [Fig. 14] was done followed by packing of silicone material (*M.P. Sai Enterprises Pvt. Ltd.*) in the mould [Fig. 15].

Retention of the prosthesis was by Medical Grade Adhesive (*Technovent- ProBond Adhesive*). The anatomical undercut present behind the ear also provided retention. Additional retention was provided by a customized stainless steel strip which had holes for mechanical interlocking by silicone material [Fig. 16]. This stainless steel strip rested on the spectacles of the patient.

Prosthesis was retrieved after 24 hours of curing at room temperature. After the finishing and polishing it was tried on the patient's face to check for the adaptation and the borders were flushed to merge well with the skin. [Fig. 17] shows the final prosthesis.

The patient was instructed to wear the twin occlusion prosthesis only while eating and the guide flange prosthesis at other times until an acceptable occlusion is achieved. Patient was trained to keep the intraoral prostheses clean as well as maintain oral hygiene. He was instructed to not wear the prostheses at night. The patient was also explained how to wear the extraoral prosthesis and how to clean the adhesive from the face.

The patient was recalled one day after the delivery of prosthesis. Thereafter he was recalled at interval of 1 week and thereafter every 1 month for next 6 months. Within a month, the patient expressed increase in masticatory efficiency and satisfaction with aesthetics.

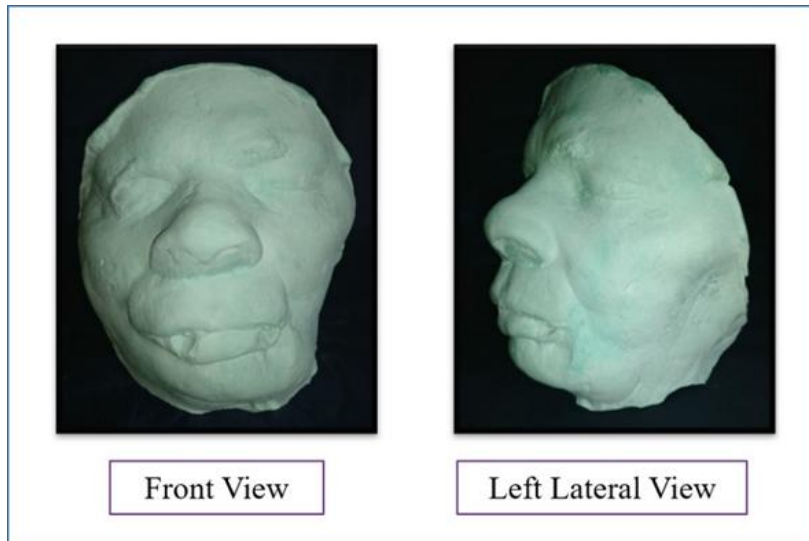


Fig. 10. Model obtained from facial moulage

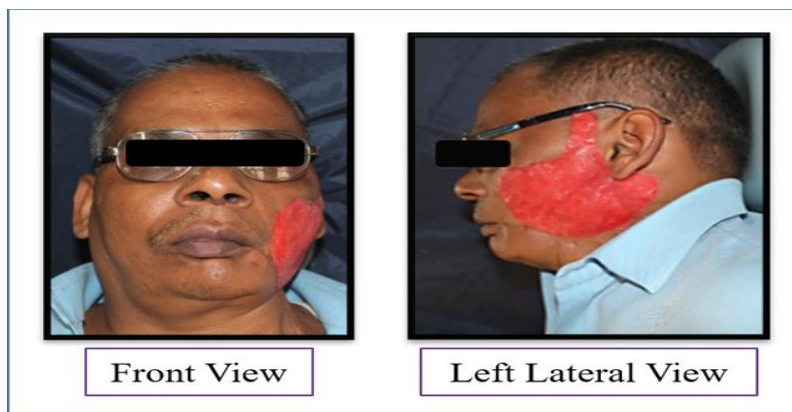

Fig. 11. Wax pattern trial for extraoral prosthesis

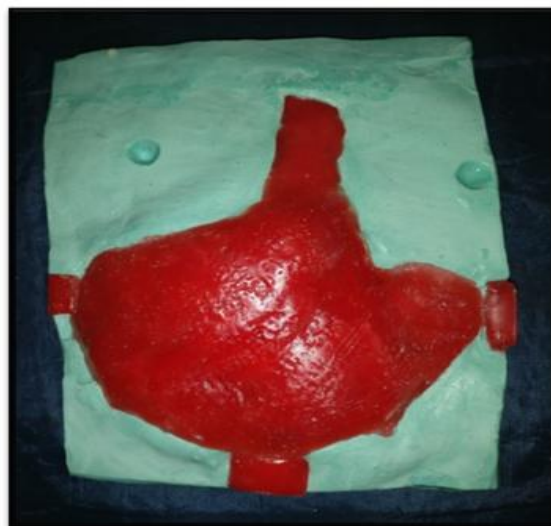


Fig. 12. Characterized wax pattern invested in type III gypsum




Fig. 13. Moulds obtained after dewaxing

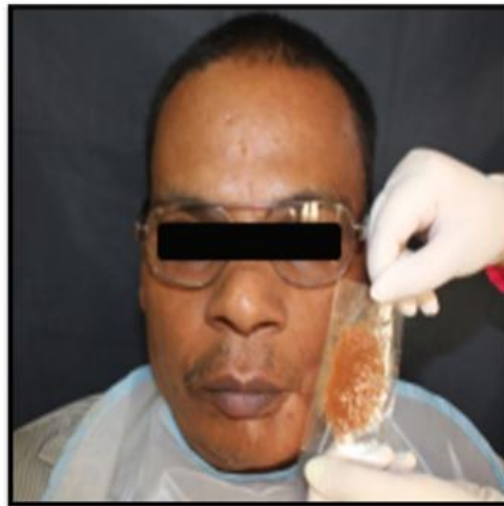

Fig. 14. Colour matching for silicone extraoral prosthesis

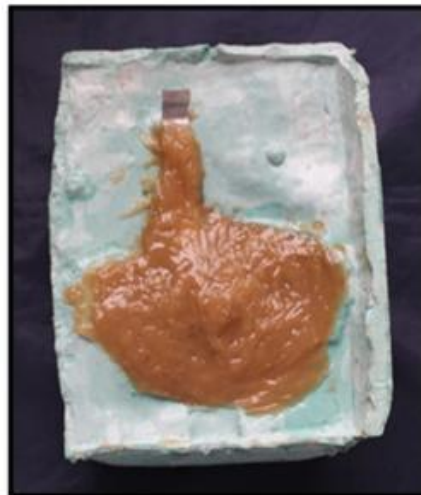

Fig. 15. Silicone material used for extraoral prosthesis




Fig. 16. Customized stainless-steel strip- for added retention

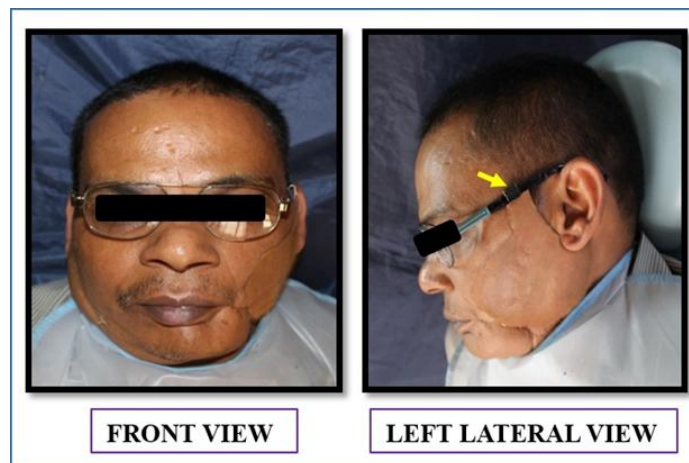


Fig. 17. Final outcome

3. DISCUSSION

In hemimandibulectomy, resection of hard and soft tissues causes loss of proprioception leading to frontal plane rotation. This results in uncoordinated and less precise mandibular movements. There is significant rotation of the remaining segment of mandible on forceful closure due to the absence of muscle attachment on the operated side [10].

Beumer et al advocates correction of deviation and frontal plane rotation of the mandible by fabricating a maxillary or mandibular guidance prosthesis followed by establishing functional occlusion. We fabricated a maxillary guide flange as it is more adjustable and preferred in severe

mandibular deviation than mandibular guidance prosthesis. The guidance prosthesis can be fabricated in cast cobalt chrome metal or acrylic resin. Since adjustments can be done in acrylic resin we opted for acrylic resin based prosthesis [2].

To facilitate mastication, twin occlusion prosthesis was fabricated by arranging an additional row of teeth on the palatal aspect in order to achieve functional occlusion.

Meeting the aesthetic needs of the patient who has undergone hemimandibulectomy is quite challenging. The use of silicone material for maxillofacial prosthesis has various advantages such as light weight, life- like appearance, ease

of intrinsic and extrinsic colouring, tissue compatibility, dimensional stability etc. The mode of retention ranges from engaging into anatomical undercuts, use of medical grade adhesives to use of spectacles, wire loops, magnets, pins, tubes etc [11,12,5]. However, in this case a combination of anatomical undercuts, medical grade adhesive and spectacles was used as retentive aids.

4. CONCLUSION

In accordance to the literature and various treatment modalities undertaken by several clinicians, a treatment plan was formulated in this case and successfully executed to rehabilitate the patient using simple and economical means and materials; and satisfactory results were obtained. The changes brought about in the patient's appearance along with functional and psychological benefits on his well-being, will indeed have an enormous impact on his personal life.

CONSENT AND ETHICAL APPROVAL

As per international standard or university standard guideline Patient's consent and ethical approval has been collected and preserved by the authors.

COMPETING INTERESTS

Authors have declared that no competing interests exist.

REFERENCES

1. Dharaskar S. MM. Guiding flange prosthesis for a patient with a hemimandibulectomy defect: A clinical report. Indo-European. Indo-European J Dent Ther Res [Internet]. 2015;4(3):291–3. Available:https://www.ijddmr.org/uploads/archive/2015/issue-3/5.pdf
2. Beumer. J, Curtis TA MM. Maxillofacial rehabilitation. Prosthodontic and surgical consideration. In. 1996;113–224.
3. Gandhimathi J, Krishnameera N, Sriramprabu G, Vinayagavel K, Sabarigirinathan C, Rupkumar P, et al. Case report a systematic approach for functional rehabilitation of hemimandibulectomy patient. 2015 ;2(3):60–2.
4. Chalian VA, Drane JB SS. Multidisciplinary practice. In 1971;294–304.
5. Gurjar R, V SKM, Rao H, Sharma A, Bhansali S. Retentive Aids in Maxillofacial Prosthodontics - A Review . 2011;2(3):84–8.
6. Dable R, Balaji P, Athavale S. Case Report Prosthetic rehabilitation of hemimandibulectomy patient. 2006;6(1):47–50.
7. R L Schneider TDT. Mandibular Resection Guidance Prosthesis: A Literature Review. J Prosthet Dent. 1986;55(1):84–6.
8. Cantor R CT. Prosthetic management of edentulous mandibulectomy patients. Part I. Anatomic, physiologic, and psychologic considerations. J Prosthet Dent. 1971;25 (4):446–57.
9. D N Firtell TAC. Removable Partial Denture Design for the Mandibular Resection Patient. J Prosthet Dent. 1982;48(4):437–43.
10. Jain L., Aeran H. SN. Prosthetic management of hemimandibulectomy patient. International journal of oral health dentistry. Int J oral Heal Dent [Internet]. 2017;3(3):195–8. Available:https://www.innovativepublication.com/journal-article-file/5096
11. Venugopalan S, Ariga P, Aggarwal P, Viswanath A. Magnetically retained silicone facial prosthesis. Niger J Clin Pract. 2014;17(2):260–4.
12. Yılmaz S, Calikoglu EO, Kosan Z. for an Uncommon Neurosurgical Emergency in a Developing Country. Niger J Clin Pract. 2019;22:1070–7.

© 2021 Vaz et al.; This is an Open Access article distributed under the terms of the Creative Commons Attribution License (<http://creativecommons.org/licenses/by/4.0>), which permits unrestricted use, distribution, and reproduction in any medium, provided the original work is properly cited.

Peer-review history:
The peer review history for this paper can be accessed here:
<https://www.sdiarticle5.com/review-history/78335>