

Unmasking Brugada Syndrome with Oral Flecainide Provocation. A Case Series of Three Patients

R. Singla^{1*}, A. Udyavar^{1,2}, A. Gupta¹, A. Bade¹, K. Munde¹ and N. O. Bansal¹

¹Department of Cardiology, Grant Medical College and JJ Hospital, Mumbai, India.

²P. D. Hinduja National Hospital, Mumbai, India.

Authors' contributions

This work was carried out in collaboration among all authors. Author RS designed the study, performed the statistical analysis, wrote the protocol and wrote the first draft of the manuscript. Authors AU and AG managed the analyses of the study. Authors AB, KM and NOB managed the literature searches. All authors read and approved the final manuscript.

Article Information

DOI: 10.9734/CA/2019/v8i430108

Editor(s):

(1) Dr. Stefano Omboni, Clinical Research Unit, Italian Institute of Telemedicine, Solbiate Arno, Varese, Italy.

Reviewers:

(1) Oscar Campuzano Larrea, Hospital Clínic de Barcelona, Spain.

(2) Massimo Bolognesi, Sports Cardiology Medicine Centre, Italy.

Complete Peer review History: <http://www.sdiarticle3.com/review-history/48994>

Case Study

Received 15 March 2019

Accepted 25 May 2019

Published 16 July 2019

ABSTRACT

The present case series discuss three patients who had brugada type 2/ type 3 like ECG pattern that was converted to type 1 pattern with oral flecainide challenge test. Brugada syndrome is associated with a high incidence of sudden cardiac death, typical ECG pattern being ST-segment elevation in the right precordial leads with T wave inversion. Pharmacological provocation should only be performed when the baseline ECG is not diagnostic of Brugada Syndrome. PR prolongation in the baseline ECG is also a contraindication because of the risk of inducing AV block. Drug challenge is performed under strict monitoring of BP and 12-lead ECG and facilities for cardio version and resuscitation are available. Atypical RBBB pattern/type 2/3 Brugada pattern on ECG in patients of syncope or family history of sudden cardiac arrest is commonly encountered by a cardiologist. This can be performed to provoke type 1 brugada pattern on ECG. Diagnosed cases of Brugada may be treated with ICD with proper indication if needed and thus prevent sudden cardiac death.

Keywords: Brugada syndrome; AV block; oral flecainide; coronary angiography.

*Corresponding author: E-mail: drrahulsingla@gmail.com;

1. INTRODUCTION

Brugada syndrome is associated with a high incidence of sudden cardiac death, typical ECG pattern being ST-segment elevation in the right precordial leads with T wave inversion. Many subjects in the community have non-type 1 Brugada pattern ECG with atypical symptoms, the relevance of which is not clear. Provocative tests to unmask type 1 Brugada pattern in these patients would help in diagnosing Brugada Syndrome. In the present case series, we will discuss three patients who had Brugada type 2/ type 3 like ECG pattern that was converted to type 1 pattern with an oral flecainide challenge test.

2. CASE REPORT

We report a case series of three persons, all of them tested positive for Flecainide provocation test.

Case 1 - A 40-year-old male presented to the emergency room with retrosternal chest pain from 2 days and intermittent palpitations with a past history of syncope. His Ekg (Fig. 1a) was recorded and showed sinus rhythm rate of 64 min with a QRS axis of 60 degrees. Lead V1 showed atypical incomplete RBBB pattern and QRS duration of 100 milliseconds with less than 2 mm elevation of J point The QTc was 390 milliseconds. Echocardiography was normal, his cardiac enzymes were borderline positive so a Coronary Angiography was planned for which revealed normal coronaries. Since the patient had a past history of syncope and baseline RBBB with type 2 Brugada like the pattern it was decided to carry out the Flecainide test.

Case 2- Second patient who was a medical student, had a history of syncope in Operation theater with no other symptoms. There was a significant positive family history of sudden cardiac death of paternal uncle at the age of 38 years was present. Ecg (Fig. 2a) recorded showed sinus rhythm with the QRS axis being 60 degrees and being 380 milliseconds. Atypical RBBB pattern with slight elevation of J point was seen in lead V1. It was decided to perform a provocation test with him as well.

Case 3 – A 46-year-old male patient was admitted to the emergency ward with a history of palpitation but no syncope. He had a history of sudden cardiac death of father 8 years back. ECG (Fig. 2a) recorded was suggestive of sinus

rhythm with a heart rate of 72 minutes with RBBB and J point elevation of less than 2 mm, QTc being 398 milliseconds with the normal axis of 50 degrees.

We subjected all the three patients with an oral loading dose of 400 mg of flecainide since the i/v formulation is not available in our country, then serial ECG was done at every 5 minutes for first 30 min and then at every 30 min for next 6 hours. The QRS duration and PR intervals and the QT – T pattern were observed. All the three patients developed typical type 1 Brugada pattern on flecainide provocation test with J point elevation more than 2 mm with downsloping /descending ST segment(Figs. 1b,2b,3b) which later returned to normal as baseline Ecg making it a positive test. None of the patients developed Ventricular tachycardia though one patient showed run of NSVT.

3. DISCUSSION

Brugada syndrome is associated with a high incidence of sudden cardiac death, typical ECG pattern of J point elevation greater than 2 mm with elevated, coved and descending ST-segment followed by T wave inversion in the right precordial leads (V₁-V₃) [1] Intensive screening among patients with aborted sudden death or syncope resulting from polymorphic ventricular tachycardia has increased the number of patients since the first report by Brugada et al. [2]. The penetrance and expressivity of disorder are highly variable ranging from lifelong asymptomatic to SCD in infancy. Brugada is mainly caused due to loss of function mutation of SCNa 5 channels [3]. The pharmacologic challenge with intravenous administration of sodium channel blockers has been suggested to unmask the ECG pattern in patients with Brugada syndrome [2,3].

Brugada Syndrome causes predominance of early depolarization currents which results in loss of action potential dome and shortening of the action potential in RVOT region causing ST-segment elevation and arrhythmic manifestations. Another theory suggests that an outward shift in the balance of currents leads to phase 2 re-entry and generation of coupled premature beats and VT/ VF [2].

A variety of drugs, such as flecainide, ajmaline, procainamide, reportedly provoke typical ST-segment elevation [2-8] because of their sodium channel blocking property. However recently

Prasad et al. [9] used flecainide both oral and iv for provocation testing in Brugada syndrome. We in the present study used oral flecainide for provocation testing. It is FDA approved for treating life-threatening ventricular arrhythmias. Flecainide which is class Ic anti-arrhythmic causes reduction in depolarizing Na current and thus may unmask underlying ECG changes. Dose [1,8] IV: 2 mg/Kg for 10 min as infusion max 150 mg and oral: 400 mg in stat doses. The sensitivity and specificity of flecainide test in SCN5A mutation-positive probands and their families have been reported as 77% and 80%,

respectively [4]. ECG monitoring (apart from continuous bedside telemetry) with normally placed 12 lead ECG and one space above right-sided leads is carried out with ECGs done every 5 min for first 30 min, and then at 30 min interval till 6 h or till abnormalities revert. The plasma half-life of flecainide is 20 hours so patients must be monitored for 24 to 48 hours post drug administration. Since only oral preparations are available in India we performed the test with oral agents Inducible Type 1 Brugada pattern in at least 2 right sided leads were considered as positive provocation test. [4-8]

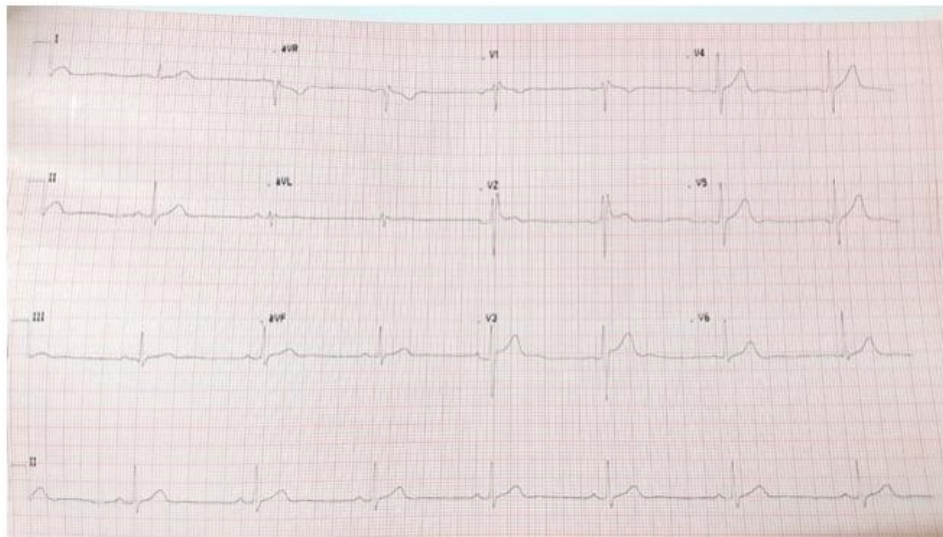


Fig. 1a. Case 1 pretest ECG showing type II pattern

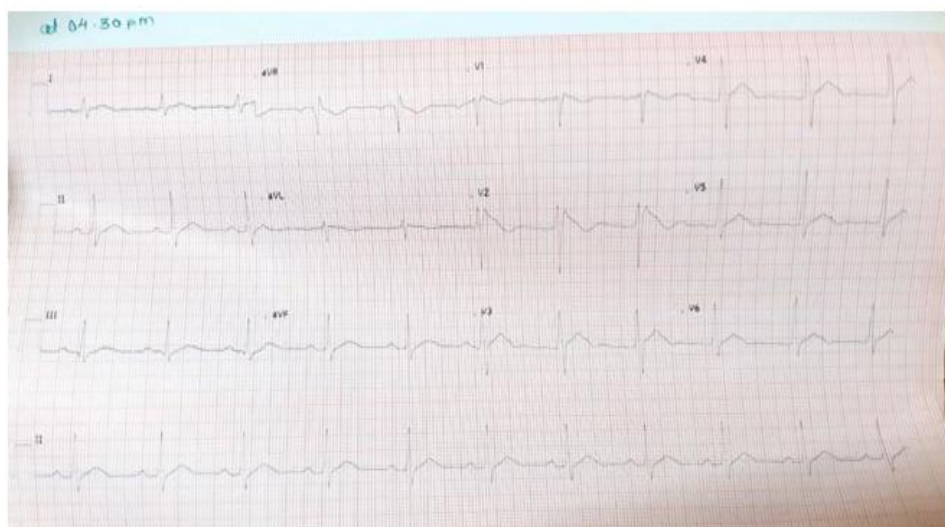


Fig. 1b. Case 1 post flecainide test ECG showing conversion to type I pattern J point elevation more than 2 mm with downsloping ST segment

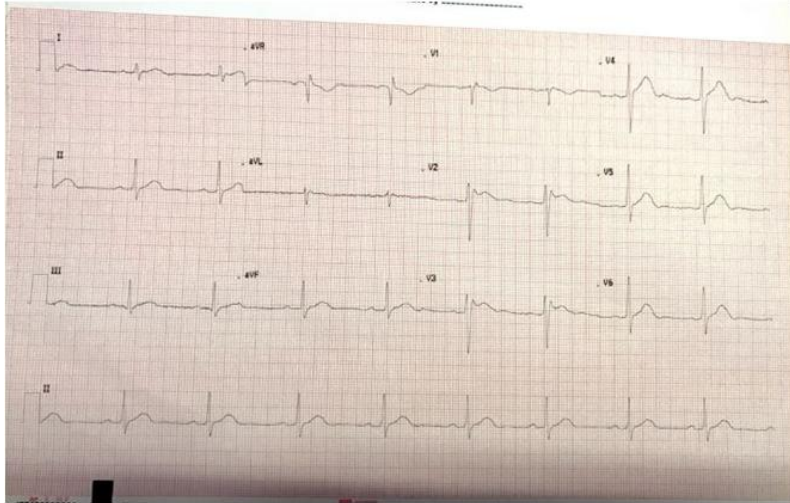


Fig. 2a. Case 2 pretest ECG showing type II pattern

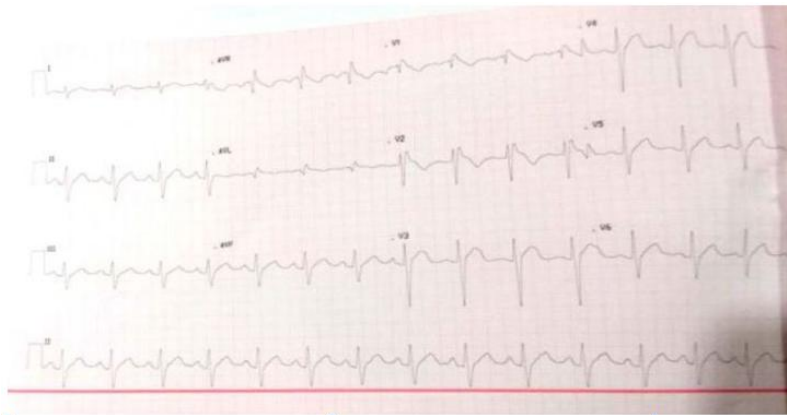


Fig. 2b. Case 2 post flecainide test ECG showing conversion to type I pattern

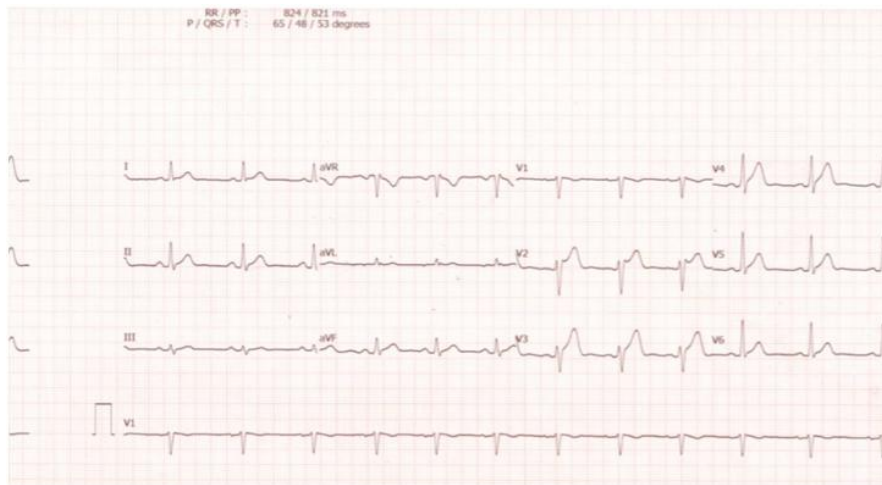


Fig. 3a. Case 3 pretest ECG showing type III pattern

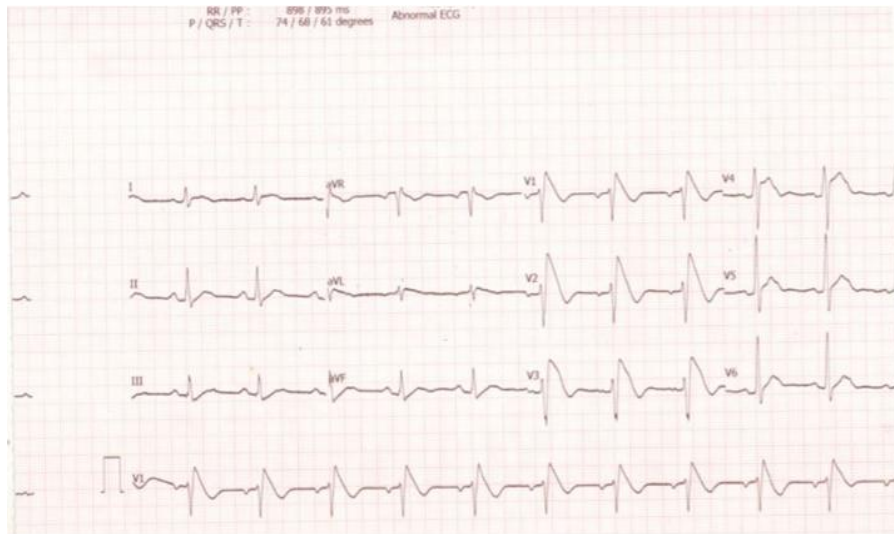


Fig. 3b. Case 3 post flecanide test ECG showing conversion to type I pattern

Pharmacological provocation should only be performed when the baseline ECG is not diagnostic of Brugada Syndrome. PR prolongation in the baseline ECG is also a contraindication because of the risk of inducing AV block. Drug challenge is performed under strict monitoring of BP and 12-lead ECG and facilities for cardioversion and resuscitation are available. Isoprenaline infusion may be employed to counteract if serious ventricular arrhythmias develop [10].

A similar study carried out on 29 patients by Prasad et al from India with non type 1 Brugada syndrome or with aborted sudden cardiac history was subjected to flecainide provocation test and 55 % of patients developed type 1 like pattern [9] which is very much similar to our current study but we selected patients that were type 2 and type 3 Brugada syndrome instead and our result was positive in all three cases.

4. CONCLUSION

Atypical RBBB pattern/type 2/3 Brugada pattern on ECG in patients of syncope or family history of sudden cardiac arrest is commonly encountered by a cardiologist. This must be taken seriously and flecainide provocation should be carried out which is a simple and cheap modality for risk stratification. This can be performed to provoke type 1 Brugada pattern on ECG. Diagnosed cases of Brugada may be treated with ICD with a proper indication if needed and thus prevent sudden cardiac death.

CONSENT

As per international standard or university standard, patient's consent has been collected and preserved by the authors.

ETHICAL APPROVAL

As per international standard or university standard written ethical approval has been collected and preserved by the author(s).

COMPETING INTERESTS

Authors have declared that no competing interests exist.

REFERENCES

1. Wilde AAM, Antzelevitch C, Borggrefe M, Brugada J, Brugada R, Brugada P. Proposed diagnostic criteria for the Brugada syndrome: A consensus report. *Circulation*. 2002;106(19):2514–2519. [PubMed]
2. Brugada R, Brugada J, Antzelevitch C, et al. Sodium channel blockers identify risk for sudden death in patients with ST-segment elevation and right bundle branch block but structurally normal hearts. *Circulation*. 2000;101:510–15.
3. Roos M, Sarkozy A, Brodbeck J, Henkens S, Chierchia GB, de Asmundis C. The importance of class-I antiarrhythmic drug test in the evaluation of patients with

- syncope: unmasking Brugada syndrome. *J. Cardiovasc Electrophysiol.* 2012;23(3): 290–295. [PubMed]
4. Priori SG, Napolitano C, Schwartz PJ, Bloise R, Crotti L, Ronchetti E. The elusive link between LQT3 and Brugada syndrome: the role of flecainide challenge. *Circulation.* 2000;29:102(9):945–947. [PubMed]
 5. Wolpert C, Echternach C, Veltmann C, Antzelevitch C, Thomas GP, Spehl S. Intravenous drug challenge using flecainide and ajmaline in patients with Brugada syndrome. *Heart Rhythm.* 2005; 2(3):254–260. [PubMed]
 6. Wilde AAM, Antzelevitch C, Borggreffe M, Brugada J, Brugada R, Brugada P. Proposed diagnostic criteria for the Brugada syndrome. *Eur Heart J.* 2002;23 (21):1648–1654. [PubMed]
 7. Reiffel JA. Does a Brugada pattern ECG precipitated by excessive-dose flecainide provide a diagnosis of a Brugada syndrome patient and/or contraindicate its use? A case study. *Circ Arrhythm Electrophysiol.* 2011;4(4):e47–51. [PubMed]
 8. Dubner S, Azocar D, Gallino S, Cerantonio AR, Muryan S, Medrano J. Single oral flecainide dose to unmask type 1 Brugada syndrome electrocardiographic pattern. *Ann Noninvasive Electrocardiol.* 2013;18(3):256–261. [PubMed]
 9. Prasad S, Namboodiri N, Thajudheen A, et al. Flecainide challenge test: Predictors of the unmasking of type 1 Brugada ECG pattern among those with non-type 1 Brugada ECG pattern. *Indian Pacing Electrophysiol J.* 2016;16(2):53-8.
 10. Shahrzad S, Khoramshahi M, Aslani A, Fazelifar AF, Haghjoo M. Clinical and electrocardiographic predictors of positive response to the intravenous sodium channel blockers in patients suspected of the Brugada syndrome. *Int J Cardiol.* 2013; 165(2):285–290. [PubMed]

© 2019 Singla et al.; This is an Open Access article distributed under the terms of the Creative Commons Attribution License (<http://creativecommons.org/licenses/by/4.0>), which permits unrestricted use, distribution, and reproduction in any medium, provided the original work is properly cited.

Peer-review history:
The peer review history for this paper can be accessed here:
<http://www.sdiarticle3.com/review-history/48994>