

Eagle's Syndrome- Enigma behind Atypical Orofacial Pain

PULKIT KHANDELWAL¹, HARISH SALUJA², SEEMIT SHAH³, ANUJ DADHICH⁴

ABSTRACT

Eagle's Syndrome (ES) is characteristically distinguished by cranio-cervico-pharyngeal signs and symptoms associated with elongation of styloid process which compresses vital neurovascular and muscular elements and other anatomical structures. Elongation of styloid process may cause intense facial pain, dysphagia, headache, otalgia, trismus, buzzing sensations and numerous other symptoms. Ossification of stylohyoid or stylomandibular ligament and/or growth of stylohyoid apophysis cause this elongation. It is not a rare condition; however, it is rarely considered as diagnosis by physicians. Definite diagnosis of this syndrome is difficult as it is frequently confounded by radiological examination, differential diagnosis and other manifestations of cervicopharyngeal pain. Non surgical management include reassurance, anti-inflammatory medications and analgesics; and surgical treatment options include a transoral or transcervical approach to resect elongated styloid process. Hereby, the author report a rare case of ES in a 45-year-old female patient who reported with pain on lateral aspect of her neck and throat bilaterally which had been present for nearly 10 years. On clinical examination, bilateral retromandibular region and tonsillar region were tender on palpation with blunt bony elevation palpable bilaterally. Computed Tomography (CT) scan revealed ossification and elongation of styloid processes bilaterally. Surgery was performed for resection of elongated styloid process bilaterally using retromandibular approach. Patient was discharged on 3rd postoperative day and her complaints resolved within seven days. Patient was symptom free and comfortable at one year postoperative follow-up.

Keywords: Elongation, Resection, Retromandibular, Styloid process, Surgery

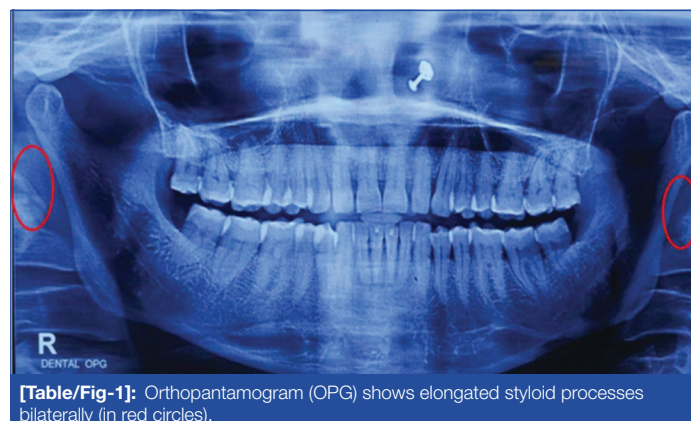
CASE REPORT

A 45-year-old female reported to Oral and Maxillofacial Surgery department with chief complaint of stabbing pain on both side of neck on neck movements, pain in throat while swallowing food and foreign body sensation in throat, since 10 years. Her pain was bilateral; either side could flare up independently, however, pain was more severe on left side. Symptoms were severe when patient would rotate her head at a specific angle and was frequently associated with disturbed sleep. Medical and dental history was non significant. There was no history of trauma to face, any surgery or any swelling in cervicofacial region. Over these preceding years, she consulted and was under treatment of various medical specialists. She received Temporomandibular Joint (TMJ) treatments, epidural injections, steroid injections, Transcutaneous Electrical Nerve Stimulation (TENS) therapy, holistic medicine therapies, ultrasound therapy, etc., to the neck but with no comfort or relief. At time of presentation, she was taking prescribed oral prednisone and analgesics for pain.

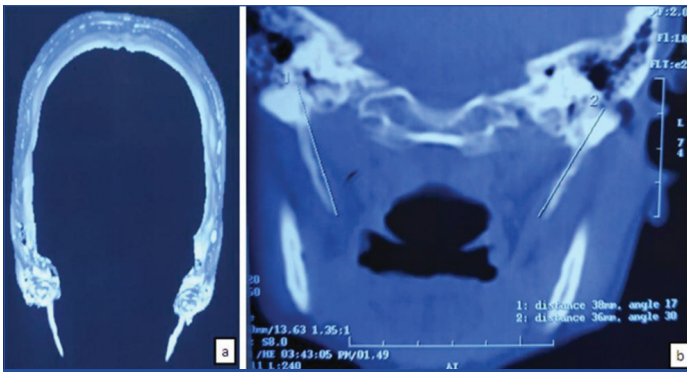
On clinical examination extraorally, on digital palpation, tenderness was present in the bilateral retromandibular region. On intraoral palpation, there was severe tenderness in bilateral tonsillar region with blunt bony elevation palpable bilaterally. None of the teeth were tender on percussion and all third molars were clinically erupted in normal position with no signs of pericoronitis. Lidocaine (2%, 1 mL) was injected into tonsillar area and symptoms subsided. Based on patient's history and clinical examination, ES was provisionally diagnosed.

Orthopantomogram (OPG) showed full set of dentition with no obvious carious or periapical lesion. However, on detailed close examination, elongated styloid processes were identified bilaterally [Table/Fig-1]. The Computed Tomography (CT) scan of the base of the skull [Table/Fig-2] revealed right styloid process measuring about 38 mm and left styloid process measuring 36 mm. Left styloid process was angled (deviated) more

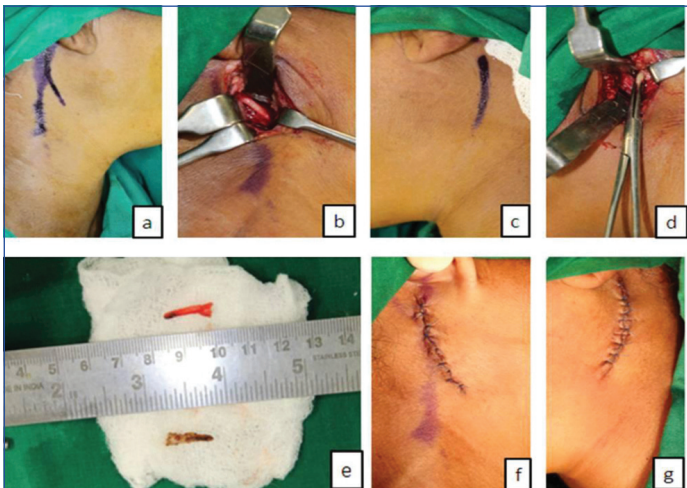
medially (30°) as compared to right one (17°). After thorough clinical and radiological correlation, final diagnosis of ES was made. Patient was explained about the condition and need for surgery. Informed consent was taken and surgery was planned under general anaesthesia. Surgery was performed and bilateral external styloidectomy was performed by lateral cervicotomy using retromandibular approach [Table/Fig-3]. A retromandibular incision was made, subplasmal skin flap was elevated, sternocleidomastoid muscle was retracted posteriorly which allowed posterior belly of digastric muscle to be identified. The parapharyngeal space was then identified and explored carefully between posterior belly of digastric muscle and mandible. Styloid process was palpated and followed back towards its origin at skull base. Overlying periosteum was stripped and styloid process was exposed. Approximately, 15 mm of caudal part of elongated styloid process was excised from both sides. Meticulous closure was done. Patient was discharged on 3rd postoperative day and antibiotics (Amoxicillin-Clavulanic acid) and analgesics (Ketorolac) were prescribed for one week. Her complaints resolved within seven days. Patient was symptom free and comfortable at one year postoperative follow-up.



[Table/Fig-1]: Orthopantomogram (OPG) shows elongated styloid processes bilaterally (in red circles).



[Table/Fig-2]: Computed Tomography (CT) scan of the base of the skull: a) Three-dimensional reconstruction showing elongated styloid process; b) Coronal CT image showing length and angulation of both styloid process
Right-38 mm length and 17° medial angulation
Left-36 mm length and 30° medial angulation.



[Table/Fig-3]: Bilateral external styloidectomy performed by lateral cervicotomy using retromandibular approach: a) Marking for incision on right side; b) Exposed elongated styloid process on right side; c) Marking for incision on left side; d) Exposed elongated styloid process on left side; e) Resected excess portion of styloid process; f-g) Final closure.

DISCUSSION

Patients with vague and indistinct orofacial and neck pain symptoms can lead to extensive and multitude of differential diagnosis. These includes pericoronitis, chronic tonsillitis, chronic tonsillo-pharyngitis, TMJ dysfunction, trigeminal neuralgia, migraine headache, glossopharyngeal neuralgia, temporal rachitis, myofascial pain dysfunction syndrome, histamine cephalgia, cluster-type headache, neck arthritis, temporal arteritis, cervical vertebral arthritis, etc., [1,2]. Very frequently missed but significant cause of such chronic pain is ES.

Since 1937, atypical/non specific orofacial pain, secondary to calcification of stylohyoid ligament or elongated styloid process, has been known as ES or stylohyoid syndrome or stylagia. These ossified structures exert pressure on numerous vital neurovascular, muscular and other anatomical structures adjoining styloid process in cervicofacial region [3,4]. Incidence of ES varies among the general population. Studies have shown that this syndrome occurs in 4% of the population, however, only 4% of such affected individuals present symptoms, thus true incidence of symptomatic ES is 0.16% [5-9]. In a 20-year study, Eagle WW reported over 200 cases of ES and stated that the normal length of styloid process is approximately 2.5-3.0 cm and a slight medial deviation of this process can result in severe and intense symptoms of atypical oro-facio-cervical pain [5,6]. He hypothesised that this syndrome is of two types: classic type and carotid artery type. The classic type of ES is often present in cases with history of tonsillectomy. It presents as pain and foreign body sensation in pharynx and throat referred otalgia, pain upon swallowing, dysphagia, hypersalivation, and rarely, temporary voice change. In the styloid-carotid artery syndrome, elongated styloid process compresses the sympathetic chain in the carotid sheath.

This can lead to pain in the eye, carotodynia, visual disturbances, dizziness and unilateral headaches [5,6,10]. Langlais RP et al., proposed radiographic classification system which includes following three types of elongated styloid process [11]:

Type I- Uninterrupted, elongated styloid process.

Type II- Single pseudo-articulation

Type III- Multiple pseudo-articulations/Segmented

On the basis of pattern of calcification, elongated styloid process is classified as calcified outline, partially calcified, nodular and completely calcified [11]. O'Carroll's classification, further modified by Thun-Szretter K et al., distinguishes four 'varieties' of styloid processes on OPG [7]:

O- Styloid processes not visible on OPG;

A- Apex of styloid process projecting above mandibular foramen;

B- Apex of styloid process situated between mandibular foramen and angle of mandible;

C- Apex of styloid process placed below mandibular angle (rare).

It was hypothesised that elongation of styloid process may occur because of congenital, reactionary, metaplastic, hormonal, genetic or idiopathic causes [1,12]. Steinmann EP proposed the following theories to explain ossification of styloid process [13]. Theory of reactive hyperplasia stated that stylohyoid ligament contains residues of its connective tissues and fibrocartilage tissues, which have potential for ossification following trauma. Theory of reactive metaplasia stated that an unusual post-traumatic healing response leads to calcification/ossification of the stylohyoid ligament. Theory of anatomic variance stated that anatomical variations may cause early elongation of styloid process or ossification of the stylohyoid ligaments [4,13].

It is a rare clinical condition with wide spectrum of symptoms, characterised by cervicopharyngeal signs and symptoms and usually presents with indistinct intense recurrent non specific cervicofacial pain, headache, foreign body sensation in throat, buzzing sensation, trismus, dysphagia, pharyngeal discomfort, change in voice, painful tongue movements, increased salivation, odynophagia, painful neck movements, radiating pain to neck, tinnitus and referred otalgia. Painful palpation at tonsillar fossa region, together with indicative clinical and radiological findings, confirms diagnosis of ES. Furthermore, pain relief gained after local infiltration of anaesthetics into tonsillar fossa corroborates the diagnosis of ES [1,6,8].

The ES is treated mainly by surgical methods and sometimes, by non surgical methods. Transpharyngeal administration of local anaesthetics or steroids in the tonsillar fossa region has been advocated, but with very lower success rate. Generally, the mainstay of treatment is surgical resection/shortening of styloid process [1]. Styloidectomy is the surgical treatment of choice. It can be performed via a transoral (transtonsillar/transpharyngeal) or extraoral (transcervical) approach [1,8,12]. Prognosis of ES is good; however surgical failures upto 20% has been reported. These failures may be attributed to iatrogenic intraoperative injury, fibrous entrapment syndrome or inadequate shortening of the styloid process [14].

CONCLUSION(S)

The ES is an unusual clinical entity that can imitate as in numerous common clinical conditions and diseases. Clinical examination of tonsillar fossa region supplemented with radiography along with diverse views and a CT scan can aid in making a definite diagnosis. Surgical shortening or resection of the elongated styloid process is the ideal treatment of choice.

REFERENCES

- [1] Pinheiro TG, Soares VYR, Ferreira DBL, Raymundo IT, Nascimento LA, de Oliveira CACP. Eagle's Syndrome. *Int Arch Otorhinolaryngol*. 2013;17(3):347-50.
- [2] Saccomanno S, Greco F, DE Corso E, Lucidi D, Delii R, D'Addona A, et al. Eagle's Syndrome, from clinical presentation to diagnosis and surgical treatment: A case report. *Acta Otorhinolaryngol Ital*. 2018;38(2):166-69.

- [3] Casale M, Rinaldi V, Quattrocchi C, Bressi F, Vincenzi B, Santini D, et al. Atypical chronic head and neck pain: Don't forget Eagle's syndrome. *Eur Rev Med Pharmacol Sci.* 2008;12:131-33.
- [4] Prabhu LV, Kumar A, Nayak SR, Pai MM, Vadgaonkar R, Krishnamurthy A, et al. An unusually lengthy styloid process. *Singapore Med J.* 2007;48:e34-36.
- [5] Eagle WW. The symptoms, diagnosis and treatment of the elongated styloid process. *Am Surg.* 1962;28:01-05.
- [6] Eagle WW. Elongated styloid process: Report of two cases. *Arch Otolaryngol.* 1937;25:584-46.
- [7] Thun-Szretter K, Jankowska M, Mąkal N, Dowżenko A. Evaluation of styloid process on the panoramic radiographs— preliminary report. *Czas Stomatol.* 2006;59:670-78.
- [8] Prasad KC, Kamath MP, Reddy JM, Raju K, Agarwal S. Elongated styloid process (Eagle's syndrome): A clinical study. *J Oral Maxillofac Surg.* 2002;60(2):171-75.
- [9] Sigdel B, Karn M, Sah K. Bilateral elongated styloid processes: Eagle syndrome. *The Lancet.* 2021;397(10282):1387.
- [10] Mendelsohn AH, Berke GS, Chhetri DK. Heterogeneity in the clinical presentation of Eagle's syndrome. *Otolaryngol Head Neck Surg.* 2006;134:389-93.
- [11] Langlais RP, Miles DA, Van Dis ML. Elongated and mineralized stylohyoid ligament complex: A proposed classification and report of a case of Eagle's syndrome. *Oral Surg Oral Med Oral Pathol.* 1986;61:527-32.
- [12] Fini G, Gasparini G, Filippini F, Becelli R, Marcotullio D. The long styloid process syndrome or Eagle's syndrome. *J Craniomaxillofac Surg.* 2000;28:123-27.
- [13] Steinmann EP. Styloid syndrome in absence of an elongated process. *Acta Otolaryngologica.* 1968;347-56.
- [14] Ghosh LM, Dubey SP. The syndrome of elongated styloid process. *Auris Nasus Larynx.* 1999;26:169-75.

PARTICULARS OF CONTRIBUTORS:

1. Associate Professor, Department of Oral and Maxillofacial Surgery, Rural Dental College, PIMS-DU, Loni, Ahmednagar, Maharashtra, India.
2. Professor, Department of Oral and Maxillofacial Surgery, Rural Dental College, PIMS-DU, Loni, Ahmednagar, Maharashtra, India.
3. Professor and Head, Department of Oral and Maxillofacial Surgery, Rural Dental College, PIMS-DU, Loni, Ahmednagar, Maharashtra, India.
4. Professor, Department of Oral and Maxillofacial Surgery, Rural Dental College, PIMS-DU, Loni, Ahmednagar, Maharashtra, India.

NAME, ADDRESS, E-MAIL ID OF THE CORRESPONDING AUTHOR:

Pulkit Khandelwal,
Associate Professor, Department of Oral and Maxillofacial Surgery, Rural Dental College,
PIMS-DU, Loni, Ahmednagar, Maharashtra, India.
E-mail: khandelwal.pulkit22@gmail.com

PLAGIARISM CHECKING METHODS: [Jan H et al.]

- Plagiarism X-checker: Jul 26, 2021
- Manual Googling: Sep 03, 2021
- iThenticate Software: Dec 28, 2021 (19%)

ETYMOLOGY: Author Origin

AUTHOR DECLARATION:

- Financial or Other Competing Interests: None
- Was informed consent obtained from the subjects involved in the study? Yes
- For any images presented appropriate consent has been obtained from the subjects. Yes

Date of Submission: **Jul 23, 2021**
Date of Peer Review: **Sep 06, 2021**
Date of Acceptance: **Sep 20, 2021**
Date of Publishing: **Jan 01, 2022**