



Post Facial Restructuring Bariatric Surgery: Case Report

Juliana Minho Jordan ^{a,b,++}, Raissa Leitão Guedes ^a,
Marilia de Oliveira Coelho Dutra Leal ^{c,#},
Silvia Aparecida Gimenes Cantele Oliani ^b,
Tarley Eloy Pessoa de Barros ^a
and Cláudio Roberto Pacheco Jodas ^{b†}

^a Foundation to Support Research and Studies in the Health Area - São Paulo, Brazil.

^b Department of Oral and Maxillofacial Surgery and Traumatology - São Leopoldo Mandic College Campinas/ Araras, Brazil.

^c Roraima Legal Medical Institute, Brazil.

Authors' contributions

This work was carried out in collaboration among all authors. Authors JMJ, RLG, and TPDB designed the study, wrote the protocol, and wrote the first draft of the manuscript. Authors MOCDL, SAGCO, and CIRPJ managed the study analyses and the literature search. All authors read and approved the final manuscript.

Article Information

DOI: <https://doi.org/10.9734/jammr/2024/v36i115625>

Open Peer Review History:

This journal follows the Advanced Open Peer Review policy. Identity of the Reviewers, Editor(s) and additional Reviewers, peer review comments, different versions of the manuscript, comments of the editors, etc are available here: <https://www.sdiarticle5.com/review-history/125104>

Case Report

Received: 16/08/2024

Accepted: 19/10/2024

Published: 30/10/2024

ABSTRACT

Aims: According to the World Health Organization (WHO), obesity is considered a chronic, progressive, and relapsing disease that poses an excessive health risk. One of the proposed treatments for obesity is bariatric surgery. However, one of the consequences of this rapid weight loss due to surgery is fat loss in the face, which is associated with facial aging.

⁺⁺ Master's Student;

[#] Forensic Expert;

[†] Professor;

*Corresponding author: E-mail: marilialeal@hotmail.com;

Cite as: Jordan, Juliana Minho, Raissa Leitão Guedes, Marilia de Oliveira Coelho Dutra Leal, Silvia Aparecida Gimenes Cantele Oliani, Tarley Eloy Pessoa de Barros, and Cláudio Roberto Pacheco Jodas. 2024. "Post Facial Restructuring Bariatric Surgery: Case Report". *Journal of Advances in Medicine and Medical Research* 36 (11):134-38. <https://doi.org/10.9734/jammr/2024/v36i115625>.

Presentation of Case: In 2020, a 57-year-old female patient complained of loss of volume and a sagging face. In 2018, the patient underwent bariatric surgery (25% weight reduction). Treatment was carried out with injectables from 2020-22, based on calcium hydroxyapatite, poly-L-lactic acid (PLLA), hyaluronic acid (HA), and botulinum toxin (TxA) type A.

Discussion: Autologous fat grafting offers good long-term results in patients with midface deficiency. Conversely, a disadvantage concerns the fat maintenance range of 20% to 80% (unpredictable number of cells surviving). In the present study, the patient preferred non-autologous injectable fillers over surgeries and autologous grafts in treating tissue sagging.

Conclusion Combined therapies provide facial volumetric replacement and improve sagging. They directly impact the self-perception and quality of life of patients who have undergone bariatric surgery using minimally invasive approaches and performed fractionally without the need for facial surgery.

Keywords: Obesity; bariatric surgery; disease.

ABBREVIATIONS

PLLA: Poly-L-lactic acid;
TXA: Botulinum toxin;
WHO: World Health Organization.

1. INTRODUCTION

According to the World Health Organization (WHO), obesity is a chronic, progressive, and relapsing disease that poses an excessive health risk. In practical terms, the WHO defines obesity as a body mass index weight (kg)/height (m²) equal to more than 30 for adults [1,2]. It is estimated that today, it is one of the biggest public health problems, an epidemic that affects around 500 million people worldwide [1,3].

Bariatric surgery is an increasingly indicated therapeutic option for obese patients. It leads to a drastic reduction in weight and medical comorbidities but also causes changes in dermal volume and quality and, consequently, the aesthetics of the face [4,5]. Combined therapies with injectables are indicated to correct tissue

ptosis associated with the face of post-bariatric individuals, with favorable results and good patient acceptance [6,7].

This work aims to report a therapeutic approach with a positive outcome for tissue reconnection in a female patient undergoing bariatric surgery. The patient achieved volumetric replacement, improvement in sagging, and facial appearance compatible with age.

2. PRESENTATION OF CASE

Patient ALSB, a female, 57 years old, attended a consultation in 2020, presenting a primary complaint of "loss of volume and sagging." In 2018, the patient underwent bariatric (Bypass surgery), achieving a 25% reduction in her body weight (initial: 110kg/ final: 70 kg). Because of the above, the following treatment was instituted using injectables based on calcium hydroxyapatite, poly-L-lactic acid (PLLA), hyaluronic acid (HA), and botulinum toxin (TxA) type A, distributed as follows (Fig. 1.):

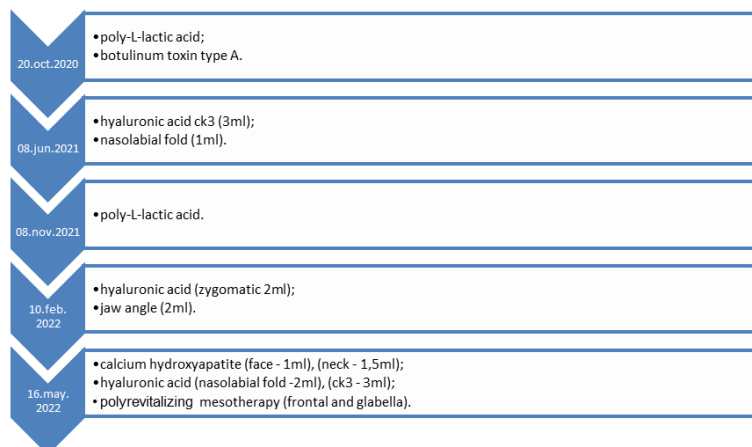


Fig. 1. Flowchart
 Source. Author (2024)

It is observed that combined therapies provide facial volumetric replacement and improve sagging (Fig. 2.).

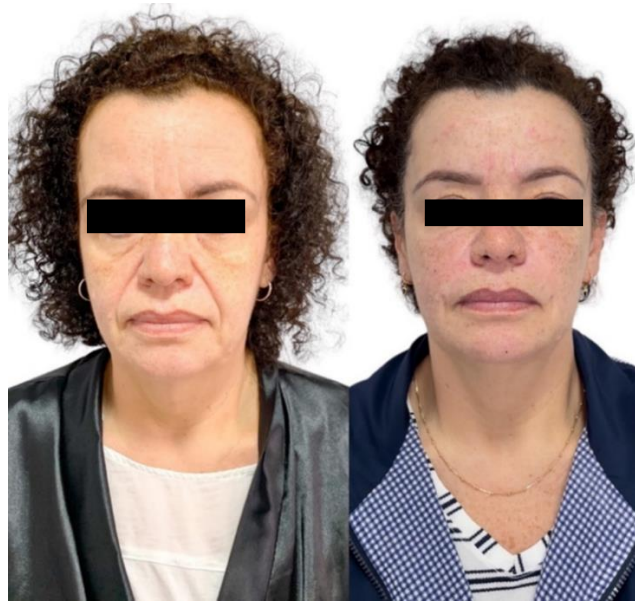

Fig. 2. Before and after treatment with minimally invasive procedures

Source. Author (2024)

3. DISCUSSION

After the excellent weight loss that occurs with bariatric surgery, it is observed that the consequences simulate the effects of aging, where there is tissue ptosis originating from the decrease in skin elasticity, a reduction in the volume of fat, as well as changes in its position, in addition to remodeling. Musculoskeletal loss, in this case, will be mainly associated with vitamin and protein deficiency [4,8]. This hypovitaminosis is the reduction in protein intake caused by the decrease in the amount of food ingested and the poor absorption of the digestive system, which suffers high levels of oxidative stress [4,6]. It is necessary to implement treatments to restore volume and treat skin quality.

Various injectables with actions in different tissue planes can be selected to restore volume and facial contour, gradually promoting tissue reconnection. Injectables can be either autologous or heterologous materials.

Autologous fat grafting offers good long-term results in patients with midface deficiency, improving volume loss and skin quality. They evaluated 14 patients with volume loss in the midface region who underwent liposuction followed by fat centrifugation with fat grafting in

the periorbital and nasolabial region. They found high patient satisfaction during long-term follow-up (12 months, n = 10 patients). Three of them required additional surgical procedures for refinement [9].

On the other hand, a disadvantage of fat grafting concerns the fat maintenance range of 20% to 80%, which makes the number of cells surviving after liposuction unpredictable. Although autologous fat is often marketed as a permanent filler, this percentage of adipocyte cell survival generates high insecurity, causing asymmetry and irregularities in the filler [10]. Not all patients are candidates for treatment with fat grafts, so a previous medical evaluation is necessary before deciding on treatment [9,10].

Patients prefer non-autologous injectable fillers over surgeries and autologous grafts in treating tissue sagging. This preference is justified by the more affordable cost and short recovery time due to the absence of incisions and open tissue manipulation [10, 11].

Injectable PLLA is a biodegradable synthetic polymer widely used to treat tissue laxity. When deposited in the subcutaneous tissue, there is an immediate swelling of the tissue due to the fluid that makes up the suspension, which disappears within a few days. The genuinely desirable

effects of improving dermal quality and thickness through firmness and elasticity will appear approximately days and months after PLLA injection, as it comes from the neo collagenases that occur as the injected particles generate an inflammatory reaction due to their degradation. With the action of collagen biostimulation from deposition in the subcutaneous tissue, an important step is sustained in restoring facial aesthetics [5, 12].

On a muscular level, TxA type A can modulate the depressor muscles, favoring a lifting effect. TxA at the insertion of the platysma muscle creates a defining impact on the mandibular contour, softening the appearance of sagging in the transition region between the jaw and neck. Furthermore, the platysma approach results in joint elevation that impacts the midface [8, 13].

HA can be injected into specific areas of the face to fill in fine lines, folds, and wrinkles, reestablishing volume and support [14]. Furthermore, several studies reveal that HA modulates growth factors when injected, thus favoring rejuvenation through tissue regeneration and not just the return of lost support volume [14-16].

4. CONCLUSION

This work presents therapeutic possibilities through combined therapies that provide facial volumetric replacement and improvement of sagging. These therapies directly impact the self-perception and quality of life of patients who have undergone bariatric surgery. Through minimally invasive approaches, the treated patient reports having regained her youthfulness.

DISCLAIMER (ARTIFICIAL INTELLIGENCE)

Authors hereby declare that NO generative AI technologies such as Large Language Models (ChatGPT, COPILOT, etc.) and text-to-image generators have been used during the writing or editing of this manuscript.

CONSENT

The patient has informed consent for this case report to be published. All authors declare that the patient gave written informed consent to publish this case report and accompanying images.

ETHICAL APPROVAL

All authors declare that all experiments have been examined and approved by the Centro de Pesquisas Odontológicas São Leopoldo Mandic SS Ethics Committee, CAAE number 77760923.9.0000.5374 and have, therefore, been performed following the ethical standards laid down in the 1964 Declaration of Helsinki.

COMPETING INTERESTS

Authors have declared that no competing interests exist.

REFERENCES

1. Pinheiro ARDO, Freitas SFTD & Corso ACT. An epidemiological approach to obesity. *Nutrition Journal*. 2004; 17(1):523-33.
2. Flegal KM, Carroll MD & Ogden CL. Prevalence and trends of obesity among adults in the United States, 1999-2000. *Jama*. 2002; 288(14):1723-7.
3. Santry HP, Gillen DL, Lauderdale DS. Trends in bariatric surgical procedures. *Jama*. 2005; 294(15):1909-17.
4. Manzoni APDS, Weber MB. Skin changes after bariatric surgery. *Brazilian Annals of Dermatology*. 2015; 90(1):157-66.
5. Baartus C, Hanke WC, Daro-Kaftan E. A decade of experience with injectable poly-L-lactic acid: focus on safety. *Dermatologic Surgery*. 2013; 39(5): 698-705.
5. Humphrey CD, Lawrence AC. Implications of Ozempic and Other Semaglutide Medications for Facial Plastic Surgeons. *Facial Plast Surg*. 2023 Dec;39(6):719-721. doi: 10.1055/a-2148-6321. Epub 2023 Aug 4. Erratum in: *Facial Plast Surg*. 2023 Dec;39(6):e1. DOI: 10.1055/s-0044-1779676. PMID: 37541662.
6. Surek CC. Facial anatomy for filler injection: the superficial musculoaponeurotic system (SMAS) is not just for facelifts. *Plastic Surgery Clinics*. 2019; 46(4): 603-12.
7. Papoian V, Mardirossian V, Hess DT & Spiegel JH. Effects of bariatric surgery on facial features. *Archives of Plastic Surgery*. 2015; 42(05): 567-71.
8. Frisenda JL, Nassif PS. Correction of the lower face and neck. *Facial Plastic Surgery*. 2018; 34(5): 480-7.

9. Prantl L, Brix E, Kempa S, Felthaus O, Eigenberger A, Brébant V & Strauss C. Facial rejuvenation with concentrated lipograft—a 12 month follow-up study. *Cells*. 2021;10(3): 594.
10. Couto RA, Charafeddine AH, Zins JE. Facelift in patients with massive weight loss. *Clin Plast Surg* 2019; 46 (04) 559-571.
11. Go BC, Frost AS, Friedman O. Use of injectable fillers for rejuvenation of the chin and jawline. *World Journal of Otolaryngology and Head and Neck Surgery*. 2023; 9 (2): 131-7.
12. Munia C, Parada M, De Alvarenga MHM. Changes in facial morphology using poly-L-lactic acid application according to the vector technique: A case series. *The Journal of Clinical and Aesthetic Dermatology*. 2022; 15(7): 38.
13. Zhou R, Fei Y, Sun, Guo J, Zhou X & Zhang X. BTX-A rejuvenation: regional botulinum toxin-A injection of the platysma in patients with facial sagging. *Aesthetic Plastic Surgery*. 2019; 43(1): 1044-53.
14. Greene JJ, Sidle DM. Hyaluronic acid fillers: current understanding of the tissue-device interface. *Facial Plastic Surgery Clinics*. 2015; 23(4): 423-32.
15. Couto RA, Waltzman JT, Tadisina KK. et al. Objective assessment of facial rejuvenation after massive weight loss. *Aesthetic Plast Surg* 2015; 39 (06) 847-855.
16. Beasley KL, Weiss MA, Weiss RA. Hyaluronic acid fillers: a comprehensive review. *Facial Plastic Surgery*. 2009; 25(02): 86-94.

Disclaimer/Publisher's Note: The statements, opinions and data contained in all publications are solely those of the individual author(s) and contributor(s) and not of the publisher and/or the editor(s). This publisher and/or the editor(s) disclaim responsibility for any injury to people or property resulting from any ideas, methods, instructions or products referred to in the content.

© Copyright (2024): Author(s). The licensee is the journal publisher. This is an Open Access article distributed under the terms of the Creative Commons Attribution License (<http://creativecommons.org/licenses/by/4.0>), which permits unrestricted use, distribution, and reproduction in any medium, provided the original work is properly cited.

Peer-review history:

The peer review history for this paper can be accessed here:

<https://www.sdiarticle5.com/review-history/125104>