



## **Shapes and Sizes of Sella Turcica Using Computerized Tomography (CT) from Tertiary Hospital in Sokoto, Nigeria**

**Z. Usman<sup>1\*</sup>, A. D. Zagga<sup>1</sup>, G. H. Yunusa<sup>2</sup>, U. Abubakar<sup>3</sup>, A. Bello<sup>1</sup>, J. D. Usman<sup>1</sup>,  
A. Abdulhameed<sup>1</sup>, S. S. Bello<sup>1</sup>, I. M. Ahmad<sup>1</sup>, M. A. Musa<sup>1</sup>, T. Ammani<sup>1</sup>,  
G. B. Marwan<sup>1</sup>, R. Bello<sup>1</sup>, A. M. Ahmed<sup>1</sup>, B. O. Onimisi<sup>1</sup> and H. A. Bunza<sup>1</sup>**

<sup>1</sup>*Department of Anatomy, Faculty of Basic Medical Sciences, College of Health Sciences,  
Usmanu Danfodiyo University, Sokoto, Nigeria.*

<sup>2</sup>*Department of Radiology, Faculty of Clinical Sciences, College of Health Sciences,  
Usmanu Danfodiyo University, Sokoto, Nigeria.*

<sup>3</sup>*Department of Radiography, Faculty of Clinical Sciences, College of Health Sciences,  
Usmanu Danfodiyo University, Sokoto, Nigeria.*

### **Authors' contributions**

*This work was carried out in collaboration among all authors. All authors read and approved the final manuscript.*

### **Article Information**

DOI: 10.9734/AJMAH/2020/v18i130175

#### Editor(s):

(1) Dr. Mohamed Salem Nasr Allah, Assistant Professor, Weill Cornell Medical College, Qatar.

#### Reviewers:

(1) R. D. Mavunda, University of Johannesburg, South Africa.

(2) Ali Al Kaissi, Orthopedic Hospital Speising, Austria.

(3) Egbe Ben Besong, University of Buea, Cameroon.

Complete Peer review History: <http://www.sdiarticle4.com/review-history/52092>

**Original Research Article**

**Received 10 November 2019**

**Accepted 18 January 2020**

**Published 24 February 2020**

### **ABSTRACT**

Cephalometry deals with measurement of body parts or radiological specimen. Sella turcica is an important anatomical structure located in the middle cranial fossa, housing the pituitary gland. Various shapes and sizes of the sellae turcica were reported. In this study, using computerized tomographic (CT) scans from a tertiary hospital, one hundred and seventy five (175) scans were analyzed using Radiant version 4.2 (Medixant 2017) for determination of sizes and shapes of the sella. Average dimensions from the study include: Length (12.4 mm), A-P diameter (14.1 mm), depth (9.6 mm) and transverse diameter (13.8 mm). Shapes were classified as being round (56.6%), oval (32%) and flat (11.4%). In another classification of shape variation, the findings are:

\*Corresponding author: E-mail: [usmanz024@yahoo.com](mailto:usmanz024@yahoo.com);

Normal (68.6%), anterior oblique (9.1%), pyramidal (6.9%), double contour floor (5.7%), notching on the posterior wall (5.1%) and sella bridge (4.6%). Males tend to have higher sella sizes than females and there is statistical significant difference between them especially in respect to A-P diameter and length parameters. However, there is no sex predilection to shapes.

*Keywords: Cephalometry; sella turcica; computerized tomography; Sokoto.*

## 1. INTRODUCTION

Cephalometry can be defined as an aspect of anthropometry that deals with the measurement of human parts such as head and face in cadavers, living subjects or radiological specimen through the use of imaging modalities [1]. The various variables measured in anthropometry include; weight, height, length, widths and thickness of the various parts of the body. These indices are used for forensic analysis as well as gender, race and age determination [2]. Sella Turcica is an important anatomical structure that lies at middle cranial fossa of the skull, containing the pituitary gland. It derives its name from the comparative shape to Turkish saddle [3]. The despondency in saddle is distinguished as pituitary fossa or hypophyseal fossa while the pituitary gland is located in the fossa. Sella turcica is bounded anteriorly by tuberculum sellae, posteriorly by dorsum sellae and inferiorly by the bony roof of the sphenoidal air sinus [4,5,6]. There are 2 (two) anterior and two (2) posterior clinoid processes. The anterior clinoid process is derived from anterior and medial projections of lesser wing of sphenoid bone, while posterior clinoid process stand for termination of dorsum sella [7,5]. Computerized Tomographic Scan (CT Scan) on the other hand, refers to ionizing radiation that is made up of an X-rays which can be used for image reconstruction using a computer. However, CT Scan has lower radiation toxicity and more costly compared to simple radiograph [8,9].

At about 8 months of intra-uterine life the body of the sphenoid bone is divided into two main parts namely; pre-sphenoid and post sphenoid parts. The demarcating point is the tuberculum sellae. The pre-sphenoid parts consist of anterior aspect of the sella turcica together with the lesser wings, while the post-sphenoid parts forms the posterior aspect of the body together with the greater wings [10]. Ossification of the sella turcica commenced immediately post-natal and is taking place at pre-sphenoid and basisphenoid parts. A common ossification center appears for tuberculum sellae and planum, even though at birth only tuberculum sellae is present. A distinct

center appears for dorsum sella [10]. Embryological distinct parts like pre-sphenoid and post-sphenoid may unite to form intersphenoid synchondrosis; so also posterior part of the sphenoid bone may unite with occiput at the clivus to form occipito-sphenoid synchondrosis. Their fusions may fail to disappear later in life. Computerized tomographic evaluation of sella turcica is clinically relevant in the following areas: Planning of neurosurgical operations related to pituitary gland abnormalities and diseases; [11] establishment of baseline data; [12,13] orthodontic treatment evaluation; [11] evaluation of sella turcica abnormalities and other cranio-facial defects [14].

Pituitary gland occupies 80% of the hypophyseal fossa and a relationship exists between the two, as changes affecting one can affect the other [4,15]. However, this relationship is variable [16]. An uncommon small sella may be seen in William's syndrome, primary hypopituitarism and growth hormone deficiency [14]. Other conditions that are associated with micro sella include: genetic dwarfism, Sheehan's syndrome, Cushing's syndrome [17].

Sometimes sella turcica enlarges without local bone erosion. This enlargement is usually associated with tumour condition, such as intrasellar adenomas (e.g prolactinoma), empty sella syndrome (intrasellar herniation of the suprasellar subarachnoid space), cranio-phangioma, Rathke's cleft cyst and aneurysm [14]. Sometimes macro sella occurs with local bone erosion and can affect parts of sella such as clinoid processes, floor, dorsum sellae. Conditions such as adenoma of the hypophysis cerebri, aneurysm, optic glioma, frontal lobe tumour and suprasellar meningioma tend to affect the anterior clinoid process [18]. However, conditions like sphenoidal sinus mucocoele, nasopharyngeal carcinoma and secondary metastasis tend to affect the sella floor causing remarkable erosion [18].

Similarly, conditions such as internal carotid aneurysm, neurofibroma, pituitary adenomas, hypothalamic tumour, posterior cranial tumours

like astrocytoma and also basilar artery aneurysm affect the various surface of the dorsum sellae together with the posterior clinoid process [10]. Furthermore, infectious conditions like tuberculosis and coccidiomycosis together with skull tumours like osteoma, osteochondroma and chondroma causes sclerotic changes in the sella turcica [10].

Increased intracranial pressure is an important sign of underlying pathology in the cranium. This important sign can be caused by hydrocephalus, intracranial tumours etc. There are several changes associated with sella turcica due to raised intracranial pressure. They include erosion of the sella floor, clinoid processes, dorsum and tuberculum sellae as well as enlargement of the hypophysis cerebri [10]. This erosion is as a result of increased osteoclastic activity leading to thinning, widening and osteoporotic changes in the affected sella turcica parts. Most often than not, suprasella or supratentorial tumours are responsible for these changes and together with non-communicating hydrocephalus leading to wearing-off of the bone and finally, destruction [18]. If the pressure is relieved, there is reversal of osteoclastic activity to osteoblastic changes within weeks and subsequent erosion have less effect than the initial one.

Changes in sella turcica of children are not prominent and visible as in adults. Some tumours and associated increased intracranial pressure conditions do not cause remarkable changes in sella shapes and size, unless they are chronic in nature and changes resolved rapidly with the treatment of the condition [10]. Other changes associated with pediatric sella turcica are hypertrophic and hypotrophic posterior clinoid process, oblique contour of the floor [19]. Oblique anterior wall sella has been documented in normal children and those with Seckel syndrome, lumbosacral myelomeningocele, Down's syndrome as well as both prenatal and postnatal fragile X [20]. Sella bridge appears when there is union between anterior and posterior clinoid process of the sella turcica [14,21]. It can be classified into type A and type B. Type A is a ribbon-like while type B is just a bony projection of either anterior or posterior clinoid process [22]. Sella bridge is a normal variant of sella shape and was reported by several workers.

Empty sella syndrome is one of the causes of sella enlargement. It is defined as the intrasellar herniation of suprasellar subarachnoid space [23]. It is the shrinking or flattening of the pituitary gland as a result of cerebrospinal fluid pressure

on the gland. It disappears on Computerized Tomography (CT) or Magnetic Resonance Image (MRI) scan and therefore called "empty sella syndrome". It can be classified into primary or secondary type. Primary type occurs if the arachnoid layer herniates into the hypophyseal fossa; while the secondary type occurs due to conditions like tumour and radiation e.t.c [24]. Due to multiple functions of the gland, symptoms such as headache, low libido, irregular or absence of menses, erectile dysfunction may occur or sometimes it will be asymptomatic. It can also be an incidental finding. However, empty sella syndrome can be treated symptomatically if it is primary type, while the secondary type is treated by taking care of the underlying cause [24].

The aim of this study is to determine the shapes and sizes of Sella Turcica using computerized tomography (CT) from Tertiary Hospital in Sokoto, Nigeria. The specific objectives are to:

1. Establish basic dimensions (length, depth and AP diameter) of sella turcica using CT scan among study population.
2. Determine presence of anatomical variations of sella turcica in study population.
3. Compare and contrast the various measurements obtained from CT scan of sella turcica between genders.

## 2. MATERIALS AND METHODS

All skull computerized tomography (CT) scans were taken in the Radiology Department of Usmanu Danfodiyo University Teaching Hospital (UDUTH), Sokoto from 2013– 2017 (a five year period) was retrieved and used for the study. This was a retrospective cross-sectional study which involved the use of one hundred and seventy five (175) skull CT scans. All the computerized tomography (CT) scans were ensured to have been taken by qualified radiographer(s) under standard condition. The scans were reported by qualified radiologist to be normal.

### 2.1 Inclusion Criteria

CT scans selection for the study was based on the following criteria:

- Good and proper positioning of the subjects.
- Absence of sella turcica abnormality
- Clarity of sella turcica dimensions

- Reported normal by qualified Radiologist.
- Only CT Scans done during the study period were retrieved.

## 2.2 Exclusion Criteria

- Skull CT scans with poor position of subjects.
- Skull CT scan with sella turcica Pathology.
- CT scans with poor quality of images.
- CTScans with incomplete information.

GE Bright Speed Multidetector Helical CT (GE Healthcare, U.S.A, 2005) Scanner was used for taking the scans. Skull computerized tomographic scans were sourced from the local database of the machine and back-up compact disc from the library. Computer monitor was used for viewing images. Proper position to ascertain symmetry or asymmetry was observed. Pathology presence or absence was noted.

Dimensions measured Computerized Tomographic (CT) Scan images were obtained from a GE Bright Speed Multidetector Helical CT (GE Healthcare,U.S.A,2005) scanner with the following parameters: 200 mAs, 120 KVp, 15 cm Field of View (FOV), 2.5 mm slice thickness, 512 x 512 matrix and a standard reconstruction algorithm. Coronal and Axial images were obtained from the scanner. The images taken were those with head of the patient in a horizontal position so that the Frankfort horizontal line was perpendicular to the table. The axial images were then reconfigured to sagittal reconstructed images for measurements using Radi Ant Version 4.2 (Medixant, 2017) Digital Imaging and Communication in Medicine (DICOM) software. Images were viewed on both soft tissue and bone windows.

Based on Silverman [25] and Kisling [26] the following dimensions were measured to determine the size of the sella turcica. The reference lines used were situated in the mid-sagittal plane (Fig. 1).

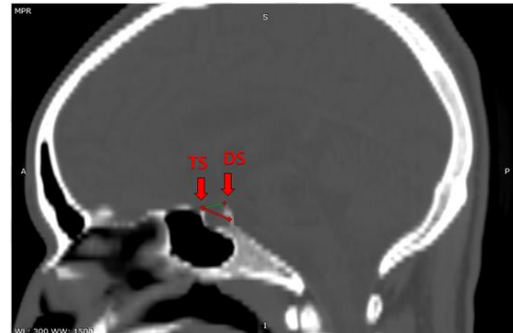
## 2.3 Length of Sella Turcica

This was measured between the tip of the tuberculum sellae (TS) to the tip of dorsum sellae (DS). It was done according to Silverman methods [25].

## 2.4 Depth of Sella Turcica

This was obtained from measuring a perpendicular line from the length above to the

deepest point on the floor of the fossa; that is the base of the pituitary fossa (BPF). This was done according to methods devised by Silverman [25].



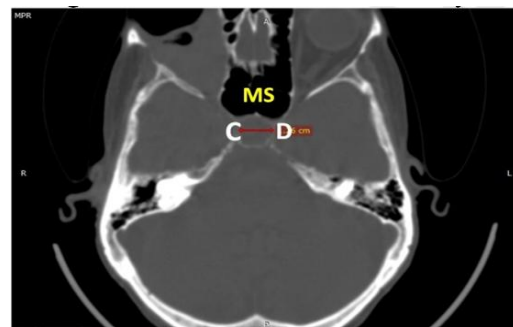
**Fig. 1. Sagittal view of CT scan of a 35 yr old male patient with round shape sella turcica. TS = Tuberculum Sellae, DS = Dorsum Sellae**

## 2.5 Antero-posterior Diameter of the Sella Turcica (apd)

It was determined by taking measurement from the tuberculum sellae (TS) to the furthest point on the posterior inner wall of the pituitary fossa, below the dorsum sellae. This is also in accordance with the method of Silverman [25].

## 2.6 Transverse Diameter

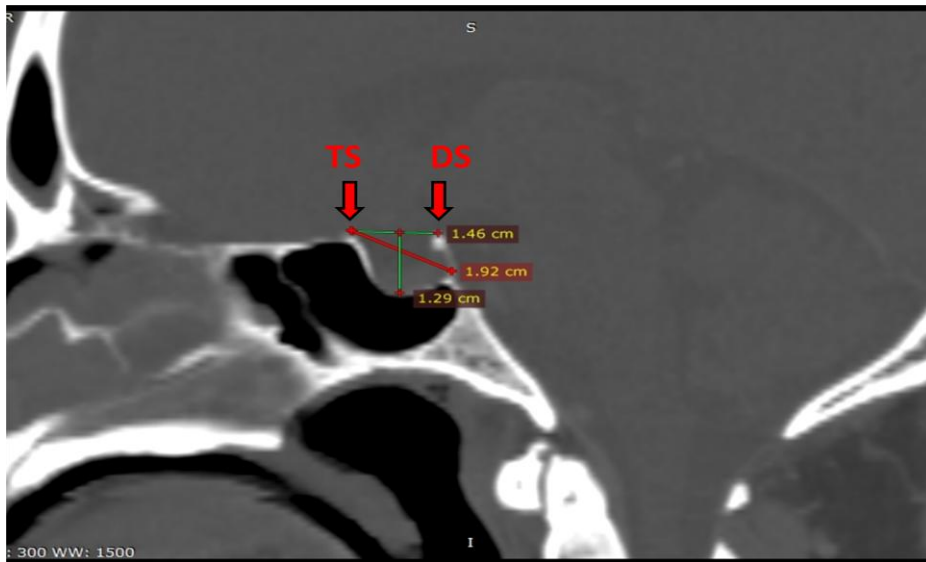
It was measured between the two (2) lateral walls of the sella turcica at their midpoints and at the same level of measurement of length and A-P diameter but only on axial plane.



**Fig. 2. Axial view of the sella turcica of 33 year old female showing measurement of the transverse diameter (C-D). MS- Maxillary Sinus**

## 2.7 Shapes of Sella Turcica

Several shapes of Sella turcica were described by different workers. Principal variations of shapes were established according to H.T. Martin [27].



**Fig. 3. Sagittal CT slide of sella turcica of a 45 year old male showing depth measurements. TS= Tuberculum Sellae, DS= Dorsum Sellae, BPF = Base of the Pituitary Fossa**

**2.8 Statistical Analysis**

Data was sorted out, tabulated and then entered into computer using Microsoft Excel manually. It was analyzed using SPSS Version 23.1. Statistical tests were employed for data analysis. Statistical significance was set at  $p < 0.05$ .

**3. RESULTS**

One hundred and seventy five (175) skull CTs of subjects with age ranging from 1 to 85 years were involved in this study. One hundred and twelve (112) subjects (64%) were males and 36% amounting to sixty three (63) females. The male to female ratio was approximately 2:1.

**3.1 Sella Turcica Dimensions**

The mean length of sella turcica was  $12.39 \pm 2.66$  standard deviation, Antero-posterior (AP) diameter was found to be  $14.12 \pm 3.06$  mm from the study, depth of  $9.57 \pm 2.30$  mm and transverse

diameter of  $13.77 \pm 3.67$  mm. Statistical significance was set at  $< 0.05$ . This was shown in Table 1.

**3.2 Sella Shape (Traditional Classification) Distribution**

Table 2 shows distribution of sella shape variations (Traditional classification) with greater proportion seen with round shape (56.6%), oval shape (32%) and least proportion seen with flat shape (11.4%).

**3.3 Sella Shape (Modern Classification) Variations**

Table 3 shows the proportion of sella shape variations (modern classification) as observed in the study with greater number described as normal (68.8%), Anterior Oblique (9.1%), Pyramidal (6.9%), Double contour floor (5.7%), Notching on the posterior wall (5.1%) and Sella bridge (4.6%).

**Table 1. Basic dimensions of sella turcica**

Parameter	Mean (mm)	Standard deviation	P value
Length	12.4	$12.39 \pm 2.66$	0.001*
A-P diameter	14.1	$14.12 \pm 3.06$	0.03*
Depth	9.6	$9.57 \pm 2.30$	0.85
Transverse diameter	13.8	$13.77 \pm 3.67$	0.439

One way ANOVA: Data are expressed as mean (SD). \* Statistically significant at  $p < 0.05$  within the parameters of length, AP diameter, Depth and Transverse diameter

**Table 2. Sella shape (traditional classification) distribution**

Shape	Frequency	Percentage (%)
Round	99	56.6
Oval	56	32.0
Flat	20	11.4

*Proportion represented in percentage (%)*

**Table 3. Sella shape (modern classification) variations**

Shape	Frequency	Percentage (%)
Normal	120	68.6
Anterior oblique	16	9.1
Pyramidal	12	6.9
Double contour	10	5.7
Notching on posterior wall	09	5.1
Sella bridge	08	4.6

*Frequency of observations represented in percentage (%)*

**4. DISCUSSION**

In this study, dimensions of sella turcica were found to be as follows: mean length 12.39 mm, mean antero-posterior diameter 14.12 mm, mean depth 9.58 mm and transverse diameter 13.77 mm. These findings were within the range of those found by Zagga, et al. [12] in his pioneering work of sella turcica cephalometry using lateral cephalographs from Sokoto, north-western Nigeria. However, the differences with this work are due to use of computerized tomographic scan and higher sample size than that of Zagga, et al. [12] Also, this current study reported higher values than those of Ogunnaike, et al. [13] whose findings were length  $9.81 \pm 0.09$  mm, mean antero-posterior diameter  $11.37 \pm 0.090$  mm and depth of 8.49 mm obtained from Lagos population, Nigeria. However, notable differences with this work include: no values of transverse diameter, use of a larger sample size than this work, differences in software used in taking measurement as well as CT scan machine configuration. Both studies agreed that males have higher sella dimensions than females unlike other workers such as Kjaer, et al. [28,14,11], who reported early age male dominance before later age equalization.

Worthy of note, is the concurrence of this study with values reported both locally and internationally. Values within the African continent include those of Osunwoke, et al. [29] whose work was among adult Nigeria population; El-sadig Ali [30] whose work is among the Sudanese population. Also, these findings were in conformity with those of Caucasians and other races as reported by several authors

[14,31,20,32,33,11] on the contrary, this work differs with other scholars by reporting higher sella dimensions when compared to those of Haider, et al. [34,16,35]. This difference may be accounted for due to differences in genetic make-up, sample size variation, use of lateral cephalographs versus CT cephalometry, conventional CT versus Cone-Beam Computerized Tomography (CBCT), software usage and deviation from the standard landmarks as used by some earlier workers.

Furthermore, this current study reported two types of anatomical shape variations. The first one include the traditional classification of the sella morphology into round (56.6%), oval (32%) and flat (11.4%). These findings are closely related to those reported by Zagga, et al. [12] using lateral cephalographs in same population. However, the study differs from Mushrath, et al. [16] who reported flat shape (28.4%), ovoid (48.1%) and round (23.4%). Also Yasin, et al. [32] reported oval shape (12.2%), round (65.3%) and flat shape (22.5%) which resembles the report of this work in terms of proportion. While the second one classified the anatomical sella turcica variation into the following: normal (68.8%), anterior oblique (9.1%), pyramidal shape (6.9%), double contour floor (5.7%), posterior wall notching (5.1%) and sella bridge (4.6%). These findings were similar with those reported by Celik-Karatas [35] in Turkish population with normal shape (68.7%), oblique anterior (16%), pyramidal shape (6%) but reported lower sella turcica bridge of 1.3%. Similarly Alkofide, et al. [11] reported normal shape of 66.7%, oblique anterior 99.4%, higher double contour floor (8.9%) and posterior wall

notching (11.1%) than this work and went further to report lower sella turcica bridge (1.1%) and pyramidal shape (2.8%) in Saudi population.

## 5. CONCLUSION

This study was able to establish basic dimensions of sella turcica using computerized tomography (CT) cephalometry (length, AP diameter, depth and transverse diameter). It was also able to established shape variations either classified into round, oval and flat or classified into normal, anterior oblique, pyramidal, double contour floor, posterior wall notching and sella bridge. Among the parameters, the length shows a greater classifying ability of 65.7% and the least ability was found with depth (49.1%). There is statistical significant difference between the sella dimensions of males and females especially with AP and length parameters. Also, males have greater sella dimensions than that of females.

## CONSENT

As per international standard, patient's written consent has been collected and preserved by the author(s).

## ETHICAL APPROVAL

The study was conducted in line with Medical Research Ethics of Helsinki Declaration of 1975 (Revised 2008). Research Ethical approval was obtained from the Ethical Committee of Usmanu Danfodiyo University Teaching Hospital, Sokoto, Nigeria.

## COMPETING INTERESST

Authors have declared that no competing interests exist.

## REFERENCES

1. Umar MBT, Singh PS, Shugaba AI. Orbital measurements among the ethnic groups of Plateau State, Nigeria. *Highland Medical Research, Ltd.* 2005;3(2):26-28.
2. Teke HY, Duran S, Canturk N, Canturk G. Determination of gender by measuring the size of maxillary sinuses in computerized tomography scans. *Surgical Radiologic Anatomy.* 2007;29:9-13.
3. Mutluer S. Sella Turcica. *Childs Nervous System.* 2006;22:333.
4. Chaurasia BD. *Human anatomy: Regional and applied, dissection and clinical volume 36<sup>th</sup> Edition.* CBS Publishers and Distributors Pvt Ltd. 2013;46-54.
5. Tadros AA, Zagga AD, Usman JD, Bello A. Tadros's atlas of human anatomy. Amal Printing and Publishing Nigeria limited, Kaduna, Nigeria. 2012;1(3):36-57.
6. Subhandra DV, Baburao S. Age and sex related morphology and morphometry of sellar region of sphenoid in prenatal and postnatal human cadavers. *International Journal Research Development Health.* 2013;1:141-48.
7. Ani S, James J Prasanth SP. Morphology of sella turcica in skeletal class II subjects. *Journal of Respiratory Practical Dentology.* 2015;10:5171.
8. Damman F, Bode A, Heuschmid M, Kopp A, Georg C, Pereira PL, Claussen CD. Multislice CT of the paranasal sinuses: First experiences using parameters of radiation dosage. *Rofo.* 2000;172(8):701-702.
9. Shahbazian M, Xue D, Hu Y, Cleynenbreuge J, Jacobs R. Spiral computed tomography based maxillary sinus imaging in relation to tooth loss, implant placement and potential grafting procedure. *Journal of Oral and Maxillofacial Research.* 2010;1(1):7-10.
10. Newton TH, Potts DG. *Radiology of the skull and brain, The Skull Book 1.* 1971;1(1):359-405.
11. Alkofide EA. The shape and size of the sella turcica in skeletal class I, class II, and class III Saudi subjects. *European Journal of Orthodontics.* 2007;29:457-463.
12. Zagga AD, Ahmed H, Tadros AA, Saidu SA. Description of the normal variants of the anatomical shapes of sella turcica. *Radiology.* 2006;899(7):187-192.
13. Ogunnaike PO, Olatunji SJ, Owolabi JO, Ginigeme AA, Olanrewaju JO. An assessment of the size of sella turcica among adult Nigerians Resident in Lagos. *International Journal of Medical Imaging.* 2016;4(3):12-6.
14. Axelsson S, Storhaug K, Kjaer I. A postnatal size and morphology of the sella turcica in Williams syndrome. *European journal of Orthodontics.* 2004;26:613-621.
15. Chang HP, Tseng YC, Chou TM. An enlarged sella turcica on cephalometric radiograph. *Dentomaxillofacial Radiology.* 2005;34:308-312.
16. Mushrath I, Alam MK, Yusof A, Kato I, Honda Y, Kubo K, Maeda H. 3 DCT study of morphological shape and size of sella turcica in Bangladeshi population. *Journal of Hard Tissue Biology.* 2017;26(1):1-6.



17. Kelestimur F. Sheehan's Syndrome. Pituitary. 2003;6(4):181-188.
18. Swallow CE, Osborne. Imaging of sella and parasellar diseases. Seminars in Ultrasound, CT and MRI. 1998;19:257-271.
19. Kurcia A, Jankowski T, Siewniak M. Sella turcica anomalies on lateral cephalometric radiographs of Polish children. Dentomaxillofacial Radiology. 2014;43(8):20140165.
20. Russell BG, Kjaer I. Postnatal structure of sella turcica in down syndrome. American Journal of Medical Genetics. 2008;87:183-188.
21. Sinnatamby CS. Last's anatomy: Regional and applied. Edinburgh; Churchill Livingstone. United Kingdom. 2011;501-504.
22. Kantor ML, Norton LA. Normal radiographic anatomy and common anomalies seen in cephalometric films. American Journal of Orthodontics and Dentofacial Orthopedics. 1987;91:414-426.
23. Weisberg LA, Zimmerman EA, Frantz AG. Diagnosis and evaluation of patients with an enlarged sella turcica. American Journal of Medicine. 1976;61:590-596.
24. Kaiser U, Ho KKY. Pituitary physiology and diagnostic evaluation. Williams Textbook of Endocrinology, 13<sup>th</sup> edition Philadelphia, PA: Elsevier. 2016;8:104-120.
25. Silverman FN. Roentgen standards for size of pituitary fossa from infancy through adolescence. American Journal of Roentgenology. 2000;28:451-460.
26. Kisling E, Copenhagen. Cranial morphology in Down's syndrome. A comparative roentgen cephalometric study in adult males. 6<sup>th</sup> edition; 1966.
27. Zimmer EA, Köhler A. Borderlands of the normal and early pathologic in skeletal roentgenology. 3<sup>rd</sup> American Edition, translated and edited by S.P. Wilk, Grune and Stratton, New York, USA; 1968.
28. Kjaer I, Hansen N, Becktor KB, Birebeak N, Balslev T. Craniofacial morphology, dentition and skeletal maturity in four siblings with Seckel syndrome. Cleft Palate Craniofacial Journal. 2001;38:645-651.
29. Osunwoke EA, Mokwe CR, Amah-Tariah FS. Radiological measurement of sella turcica in adult Nigerian population. International Journal of Clinical Pharmacology Research. 2014;4:115-117.
30. Ali-Sadiq AA. Characterization and Measurement of sella turcica among sudanese using CT" A thesis submitted for the partial fulfillment of the requirements of the Award of the MSc Degree in Diagnostic Radiological Technology of the College of Postgraduate Studies Sudan University of Science and Technology; 2013.
31. Asad S, Hamid W. Assessment and comparisons of dimensions of sella turcica in skeletal class I and skeletal class II cases. Paskitan Oral and Dental Journal. 2005;25:59-64.
32. Yasin Y, Bayrakdar IS, Ocak A, Duman SB, Dedeoglu N. Evaluation of sella turcica shape and dimensions in cleft subjects using cone-beam computed tomography. Medical Principles and Practice. 2016;26(3):280-285.
33. Sakran AMEA, Khan MA, Altaf FAN, Faragalla HEH, Mustafa AYAE, Hijazi MM, Niyazi RA, Tawakul AJ, Malebari AZ, Salem AA. A morphometric study of the sella turcica; gender effect. International Journal of Anatomy and Research. 2015;3(1):927-934.
34. Haider AH, Alam MK, Abdullah YJ, Nakano J, Yusa T, Yusof A, Osuga N. 3 DCT morphometric analysis of sella turcica in iragi population. Journal of Hard Tissue Biology. 2016;25(3):227-232.
35. Celik-Karatas RM, Kahraman FB, Akin M. The shape and size of the sella turcica in Turkish subjects with different skeletal patterns. European Journal of Medical Sciences. 2015;2(3):65-71.

© 2020 Usman et al.; This is an Open Access article distributed under the terms of the Creative Commons Attribution License (<http://creativecommons.org/licenses/by/4.0>), which permits unrestricted use, distribution, and reproduction in any medium, provided the original work is properly cited.

*Peer-review history:*

*The peer review history for this paper can be accessed here:*

<http://www.sdiarticle4.com/review-history/52092>